

Significance of hepatic preneoplasia for cancer chemoprevention

P. Bannasch, D. Nehrbass and A. Kopp-Schneider

Hepatic preneoplasia represents an early stage in neoplastic development, preceding both benign and malignant neoplasia. This applies particularly to foci of altered hepatocytes (FAH), that precede the manifestation of hepatocellular adenomas and carcinomas in all species investigated. Morphological, microbiobiochemical and molecular biological approaches *in situ* have provided evidence for striking similarities in specific changes of the cellular phenotype of preneoplastic FAH emerging in experimental and human hepatocarcinogenesis, irrespective of whether this was elicited by chemicals, hormones, radiation, viruses or, in animal models, by transgenic oncogenes or *Helicobacter hepaticus*. Different types of FAH have been distinguished and related to three main preneoplastic hepatocellular lineages: (1) the glycogenotic-basophilic cell lineage, (2) its xenomorphic-tigroid cell variant, and (3) the amphophilic-basophilic cell lineage. The predominant glycogenotic-basophilic and tigroid cell lineages develop especially after exposure to DNA-reactive chemicals, radiation, hepadnaviridae, transgenic oncogenes and local hyperinsulinism, their phenotype indicating initiation by insulin or insulinomimetic effects of the oncogenic agents. In contrast, the amphophilic cell lineage of hepatocarcinogenesis has been observed mainly after exposure of rodents to peroxisome proliferators that are not directly DNA-reactive or to hepadnaviridae, the biochemical pattern mimicking an effect of thyroid hormone, including mitochondrial proliferation and activation of mitochondrial enzymes. Hepatic preneoplastic lesions are increasingly used as end-points in carcinogenicity testing, particularly in medium-term carcinogenesis bioassays. This has been complemented more recently by the use of FAH as indicators of chemoprevention, although possible pitfalls of this approach have to be considered carefully. Our ever-increasing knowledge on the metabolic and molecular changes that characterize preneoplastic lesions and their progression to neoplasia provides a new basis for rational approaches to chemoprevention by drugs, hormones or components of the diet.

Introduction

Hepatocellular carcinoma (HCC) is one of the most frequent malignant neoplasms in humans, and has a very poor prognosis. Primary and secondary prevention appear to be the most promising approaches in the fight against this fatal disease. Chronic infection with the hepatitis B (HBV) and C (HCV) viruses, ingestion of foodstuffs contaminated with chemical hepatocarcinogens, particularly the naturally occurring mycotoxin aflatoxin B₁, and abuse of alcoholic beverages have been identified as major risk factors for the development of HCC (Bosch, 1997; Montesano *et al.*, 1997; Stuver, 1998). At least some of these factors may act synergistically, as suggested particularly for HBV and aflatoxins by epidemiological observations. Vaccination against HBV has been intro-

duced in several high-risk areas for HCC and the first results are promising (Chang *et al.*, 1997). However little, if any, progress has been made in prevention of HCC due to other risk factors.

For most of the risk factors for human HCC, appropriate animal models, including chronic infection of woodchucks with the woodchuck hepatitis virus (WHV) which is closely related to HBV, have been established (Okuda & Tabor, 1997). These models were instrumental in the analysis of the mechanism of hepatocarcinogenesis, and especially that of hepatic preneoplasia (Bannasch, 1996). Preneoplastic foci of altered hepatocytes (FAH) precede the manifestation of both benign (adenoma) and malignant hepatocellular neoplasms by long lag periods, which may vary between months and years depending on the

cause of neoplastic development and the life span of the species affected. FAH were discovered more than three decades ago in rodents treated with nitrosamines (Bannasch, 1968; Friedrich-Freksa *et al.*, 1969) and have since been observed in a large number of species, including non-human primates and humans, after exposure to hepatocarcinogenic agents of virtually all known classes, such as various chemicals, hormones, HBV, HCV, WHV, *Helicobacter hepaticus* and radiation with X-rays, neutrons or α -particles from Thorotrast. FAH have also been found in transgenic rodent strains and a mutant (LEC) rat strain suffering from hereditary hepatitis, which are prone to develop a high incidence of HCC (Grisham, 1996; Bannasch & Schröder, 2001). FAH have been studied most extensively in rodent models of chemical hepatocarcinogenesis (Hasegawa & Ito, 1994; Pitot & Dragan, 1994; Farber, 1996; Bannasch & Zerban, 1997), and have been increasingly used as endpoints in carcinogenicity testing (Bannasch, 1986; US National Institute of Environmental Health Sciences, 1989), particularly in risk identification by medium-term carcinogenesis bioassays (Ito *et al.*, 1998; Williams & Enzmann, 1998). More recently, FAH have also been used as biomarkers for studying chemopreventive effects in experimental hepatocarcinogenesis. Although this approach appears to be attractive, it is evident that only detailed knowledge of the pathobiology of the preneoplastic lesions and of the various animal models of hepatocarcinogenesis employed can avoid pitfalls in the evaluation of possible chemopreventive effects.

Cellular origin of HCC and definition of preneoplasia

There is continuing debate on the existence of potential stem-like liver cells which might be identical with, or closely related to, the so-called oval cells derived from the cholangioles, and might give rise to both cholangiocellular and hepatocellular carcinomas (Kitten & Ferry, 1998; Lazaro *et al.*, 1998; Steinberg *et al.*, 1999). While there is general agreement that oval cells may be precursors of cholangiocellular neoplasms, their role in the evolution of hepatocellular neoplasms remains controversial (Bannasch & Zerban, 1997). In experimental chemical hepatocarcinogenesis, it has been clearly shown that the dose determines whether

the carcinogenic process is accompanied by oval cell proliferation. Only after exposure to high doses that lead to pronounced toxic damage of the liver parenchyma does oval cell proliferation occur frequently early during hepatocarcinogenesis. A similar dose-dependence has been observed for development of liver fibrosis and cirrhosis. These findings show clearly that neither oval cell proliferation nor liver cirrhosis is an obligatory prerequisite for development of HCC. In contrast, FAH appear at all dose levels that lead to HCC, irrespective of whether cirrhotic changes or oval cell proliferation occur. Evidence for the preneoplastic nature of FAH has been provided by a number of laboratories (Hasegawa & Ito, 1994; Pitot & Dragan, 1994; Farber, 1996; Bannasch & Zerban, 1997; Williams & Enzmann, 1998), hepatic preneoplasia being defined as phenotypically altered cell populations that have no obvious neoplastic nature but indicate an increased risk for the development of both benign and malignant neoplasms (Bannasch, 1986). The earliest-emerging FAH are composed of differentiated hepatocytes, which show specific morphological, metabolic and molecular aberrations, and gradually dedifferentiate, while progressing through various intermediate forms to the malignant phenotype.

Pathomorphology of preneoplastic hepatocellular lineages

Experimental chemical hepatocarcinogenesis

For a long time, hepatic preneoplasia as defined above was almost exclusively studied during experimental hepatocarcinogenesis in rodents. On the basis of cytomorphological and simple cytochemical criteria, resulting mainly from staining of alcohol-fixed serial sections with haematoxylin and eosin (H&E) and the periodic acid-Schiff reaction (PAS) to reveal glycogen, at least eight different types of preneoplastic FAH have been distinguished (Bannasch & Zerban, 1992; Goodman *et al.*, 1994). Comprehensive sequential morphological, stereological and biochemical studies *in situ* revealed that the different phenotypes of FAH are integral parts of preneoplastic hepatocellular lineages leading from highly differentiated hepatocellular phenotypes to poorly differentiated neoplastic phenotypes. Three main hepatocellular lineages have been distinguished (Figure 1): (1) the glycogenotic-basophilic, (2) the xenomorphic-

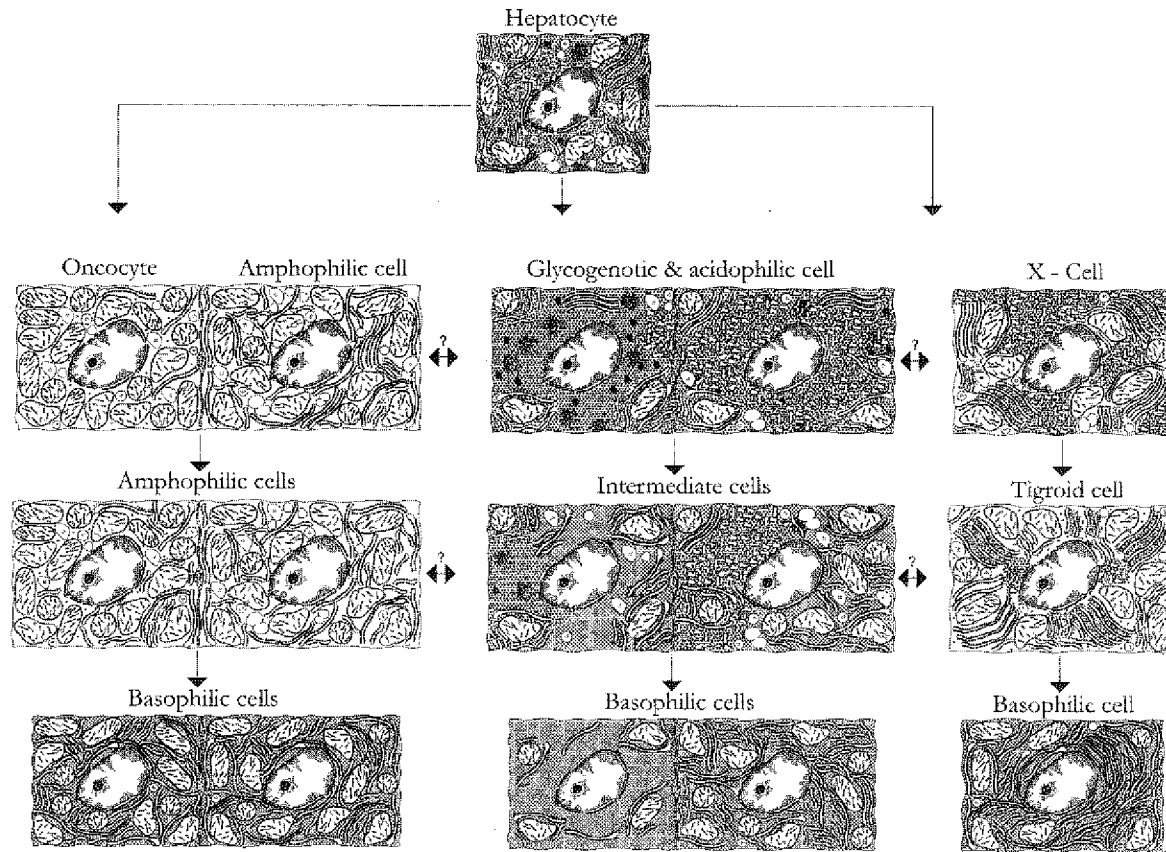


Figure 1. Schematic diagram of hepatocellular lineages emerging in rodent liver during hepatocarcinogenesis.

The predominant sequence of cellular changes (centre) starts with glycogenotic clear and acidophilic (smooth endoplasmic reticulum-rich) hepatocytes and progresses through intermediate phenotypes in mixed cell populations to glycogen-poor, homogeneously basophilic (ribosome-rich) cellular phenotypes prevailing in undifferentiated hepatocellular carcinomas. The tigroid basophilic cell lineage (to the right), originating from xenomorphic hepatocytes (X-cells), is characterized by cells with abundant highly ordered stacks of the rough endoplasmic reticulum and apparently represents a less altered variant of the glycogenotic-basophilic cell lineage. The amphophilic cell lineage (to the left), which has hitherto been described mainly in rats treated with nongenotoxic peroxisome proliferators, and may include oncocytes in woodchucks chronically infected with the woodchuck hepatitis virus, consists of cells with a glycogen-poor cytoplasm containing both abundant granular-acidophilic (mitochondria and peroxisomes) and basophilic (ribosomes) components (from Bannasch, 1998).

tigroid, and (3) the amphophilic-basophilic cell lineage (Bannasch, 1996). After exposure of rats to the majority of hepatocarcinogenic chemicals, especially DNA-reactive compounds, the glycogenotic-basophilic lineage prevails. The sequence of cellular changes in this lineage starts with the appearance of glycogenotic clear and acidophilic cell foci and passes through mixed cell populations before formation of glycogen-poor, basophilic (ribosome-rich) neoplastic lesions. This progression-linked phenotypic instability is associated with a gradual reduction of the glycogen initially stored in excess, a multiplication of ribosomes resulting in increased cytoplasmic basophilia, and an ever-increasing cell proliferation and expansion from small to large foci (Bannasch, 1968; Moore & Kitagawa, 1991; Bannasch & Zerban, 1997). Although a minor but significant increase of cell proliferation is seen in the earliest glycogenotic foci, there is an inverse relationship between the gradual reduction of glycogen and the pronounced increase in cell proliferation during neoplastic development at later time points (Zerban *et al.*, 1994). The xenomorphic-tigroid cell lineage represents a less altered variant of the glycogenotic-basophilic cell lineage (Weber & Bannasch, 1994; Ströbel *et al.*, 1998).

In contrast, the amphophilic cell lineage is characterized by a completely different phenotype, frequently produced in rat liver by hepatocarcinogens that are not directly DNA-reactive, of the peroxisome proliferator type, including several hypolipidaemic drugs and the adrenal steroid hormone dehydroepiandrosterone (Weber *et al.*, 1988; Metzger *et al.*, 1995). The amphophilic cell foci, synonyms of which are 'atypical eosinophilic foci' (Harada *et al.*, 1989), 'weakly basophilic foci' (Marsman & Popp, 1994), and 'large-cell basophilic foci' (Christensen *et al.*, 1999), are not preceded by glycogenotic foci under most experimental conditions, but are poor in glycogen from the beginning. At the ultrastructural level, the amphophilic cells exhibit a proliferation of mitochondria wrapped by profiles of rough endoplasmic reticulum, and sometimes also an increase in peroxisomes (Metzger *et al.*, 1995). During progression to the malignant phenotype, the number of ribosomes and, consequently, the cytoplasmic basophilia usually increase.

A series of stereological studies based on the morphological classification of FAH confirmed the progression-linked phenotypic instability of the predominant preneoplastic hepatocellular lineage (Table 1), and revealed that the number, size and phenotype of FAH is dose- and time-dependent, correlating with the appearance of hepatocellular adenomas and carcinomas (Moore & Kitagawa, 1986; Enzmann & Bannasch, 1987; Weber & Bannasch, 1994c). The results of these investigations also support previous observations (Moore & Kitagawa, 1986; Farber & Sarma, 1987; Bannasch & Zerban, 1992, 1997) that a reversion-linked phenotypic instability of FAH may occur under certain experimental conditions, especially after repeated but limited administration of high sublethal doses of a single or several carcinogenic chemicals, leading to reappearance of less altered phenotypes after withdrawal of these agents (Weber & Bannasch, 1994a,b,c). The cause of reversion-linked phenotypic instability is poorly understood, but it may be due mainly to the cessation of a proliferative stimulus elicited during carcinogen exposure by severe toxic parenchymal damage.

Experimental physical, viral and hormonal hepatocarcinogenesis

In the past few years, it has been shown that the glycogenotic-basophilic and tigroid-xenomorphic lineages develop not only in experimental hepatocarcinogenesis induced by chemicals such as nitrosamines, aflatoxin B₁ and phenobarbital, but also in animal models of physical, viral and hormonal hepatocarcinogenesis (Table 2). In addition to neutrons and α -particles from Thorotrast (Ober *et al.*, 1994), X-rays have been reported to produce the glycogenotic-basophilic cell lineage (Oehlert, 1978). Particularly rewarding for the understanding of human hepatocarcinogenesis are the findings in the woodchuck model of hepadnaviral hepatocarcinogenesis (Toshkov *et al.*, 1990; Radaeva *et al.*, 2000) and in the transgenic mouse models established by Chisari (Toshkov *et al.*, 1994) and Kim *et al.* (1991), in which subgenomic fragments of HBV, coding for the large envelope polypeptide and the X protein, respectively, are expressed and trigger the development of hepatocellular carcinomas.

Table 1. Chemical hepatocarcinogenesis: characteristics of preneoplastic cellular changes

- **Early emergence** of foci of altered hepatocytes (FAH) in all models of chemical hepatocarcinogenesis
- **Phenotypic diversity and instability**
- Integration of certain types of FAH in **three main hepatocellular lineages**
- **Dose- and time-dependence** of number, size, and phenotype of FAH correlates with appearance of hepatocellular neoplasms
- **Progression-linked phenotype instability** is associated with ever-increasing **cell proliferation** (and apoptosis) and **FAH expansion**
- **Reversion-linked phenotypic instability** results in reappearance of early preneoplastic phenotypes but not in normal liver parenchyma
- Lack of consistent **genotypic changes** in FAH
- **Field effects** rather than repeated clonal selections characterize progression of FAH
- Mathematical modelling of phenotypic cellular changes as **epigenetic events**

Table 2. Hepatocellular lineages in animal models of hepatocarcinogenesis**Glycogenotic-basophilic/xenomorph-tigroid cell lineages**

- Chemicals: nitrosamines, aflatoxin B₁, thioacetamide, phenobarbital
- Radiation: X-rays, neutrons, α -particles of Thorotrast
- Viruses: woodchuck hepatitis virus, subgenomic fragments of hepatitis B virus and simian virus 40
- Insulin: intrahepatic transplantation of pancreatic islets in diabetic rats

Amphophilic-basophilic cell lineage

- Chemicals: peroxisome proliferators including dehydroepiandrosterone
- Virus: woodchuck hepatitis virus

The amphophilic-basophilic cell lineage has also been observed in experimental chemical, hormonal and hepadnaviral hepatocarcinogenesis (Bannasch *et al.*, 1995; Metzger *et al.*, 1995; Dombrowski *et al.*, 2000; Radaeva *et al.*, 2000). However, while the glycogenotic-basophilic and amphophilic-basophilic cell lineages are produced by different types of chemicals in the rat, they fre-

quently coexist in hepadnaviral hepatocarcinogenesis in woodchucks.

Human hepatocarcinogenesis

In resected livers from humans suffering from liver cell cancer and cirrhosis as a consequence of a variety of chronic liver diseases predisposing to HCC (Table 3), FAH comparable to those observed in

Table 3. Hepatocellular lineages in human hepatocarcinogenesis

Glycogenotic-basophilic cell lineage

- HCC-bearing livers with and without cirrhosis
- Posthepatic cirrhosis (hepatitis B virus or hepatitis C virus)
- Alcoholic cirrhosis
- Biliary cirrhosis
- Cryptogenic cirrhosis
- Inborn hepatic glycogenosis

Amphophilic cell populations

- Frequent appearance under similar conditions, except inborn hepatic glycogenosis

animal models are often found (Altmann, 1994; Bannasch, 1996). We have evidence for the preneoplastic nature of the glycogenotic-basophilic cell lineage (Bannasch *et al.*, 1997b; Su *et al.*, 1997), but this remains to be demonstrated for the amphophilic cell population in human hepatocarcinogenesis. Cases of inborn hepatic glycogenosis, which result from a genetically fixed defect of glucose-6-phosphatase and are associated with a high risk of developing hepatocellular neoplasms when the patients pass through adolescence, seem to be of particular heuristic value (Bannasch *et al.*, 1984; Bianchi, 1993).

Pathobiochemistry of preneoplastic hepatocellular lineages

The abnormal morphology of FAH is associated with a variety of biochemical and molecular aberrations, as demonstrated by cytochemical, microbiochemical and molecular biological methods (Moore & Kitagawa, 1986; Farber & Sarma, 1987; Schwarz *et al.*, 1989; Pitot, 1990; Farber, 1996; Bannasch *et al.*, 1997a; Mayer *et al.*, 1998a; Feo *et al.*, 2000a). Aberrations in energy and drug metabolism have attracted the most attention, but other metabolic pathways may also be affected. Resistance to experimentally induced haemolysis was introduced as a marker of various

types of FAH (including glycogen storage foci) in rodents (Williams *et al.*, 1976) and has been successfully applied to the detection of FAH in human hereditary haemochromatosis (Deugnier *et al.*, 1993). Similarly, excessive storage of glycogen (glycogenosis) and reduced activity of glucose-6-phosphatase, which were the first biochemical markers of FAH discovered in rodents (Bannasch, 1968; Friedrich-Freksa *et al.*, 1969), have been valuable for the identification of corresponding focal lesions in human liver (Bannasch *et al.*, 1997b). Among the enzymes involved in drug metabolism, γ -glutamyltranspeptidase (γ GT) (Kalengayi *et al.*, 1975) and the placental form of glutathione S-transferase (GSTP) (Sato *et al.*, 1984) have been widely used as markers for FAH (Sato, 1989). It is important to realize, however, that the three preneoplastic hepatocellular lineages differ fundamentally in not only their morphological but also their biochemical phenotype. Thus, while γ GT and GST-P are reasonable markers for FAH of the glycogenotic-basophilic cell lineage, they fail to reveal the majority of tigroid cell foci (Ströbel *et al.*, 1998), and are completely absent from amphophilic cell foci (Rao *et al.*, 1982; Mayer *et al.*, 1998a). Changes in the expression of certain genes, including those coding for various growth factors, and molecular genetic alterations, most of which were not studied in specific types of FAH and showed considerable interspecies variations, are considered by Grisham (1996), Bannasch & Schröder (2001) and Feo *et al.* (2000a).

We have studied the biochemical phenotype of the two main preneoplastic hepatocellular lineages, the glycogenotic-basophilic and the amphophilic-basophilic lineages, using the nitrosamine-induced stop model of rat hepatocarcinogenesis (Bannasch, 1968) and rat liver continuously exposed to dehydroepiandrosterone (Metzger *et al.*, 1995; Mayer *et al.*, 1998a). The preneoplastic FAH occupy a maximum of 10% of the total liver volume, precluding the application of conventional biochemical or molecular biological approaches in tissue homogenates. We have, therefore, adopted enzyme histochemical, immunohistochemical, microbiochemical and molecular biological methods *in situ* (Bannasch *et al.*, 1984, 1997a). Based on these approaches, metabolic and molecular patterns in the predominant types of preneoplastic hepatic foci have been outlined.

Phenotypes mimicking a response to insulin

In the glycogenotic foci, several metabolic changes apparently act in concert favouring glycogen accumulation (Bannasch *et al.*, 1997a; Mayer *et al.*, 1998b). In addition to inactivation of the adenylylase-mediated signalling pathway, resulting in disturbance of phosphorylytic glycogen breakdown, the hydrolytic lysosomal degradation of glycogen by α -glucosidase is reduced. Decreased activity of glucose-6-phosphatase and expression of the glucose transporter protein GLUT2 indicate a downregulation of gluconeogenesis (Grobholz *et al.*, 1993). In contrast, increased activities of the key enzymes pyruvate kinase and glucose-6-phosphate dehydrogenase point to upregulation of glycolysis and the pentose phosphate pathway, providing precursors and energy for nucleic acid synthesis associated with increased cell proliferation (Hacker *et al.*, 1982, 1998; Klimek *et al.*, 1984). This metabolic pattern is consistent with an insulinomimetic effect of the oncogenic agents (Klimek & Bannasch, 1993; Bannasch *et al.*, 1997a). Direct evidence for such an effect in the early stages of hepatocarcinogenesis has been provided by a new animal model of hormonal hepatocarcinogenesis. Low-number intraportal pancreatic islet transplantation in streptozotocin-diabetic rats results in rapid development of proliferative focal lesions, the morphological and biochemical phenotype of which is similar to that induced by a variety of oncogenic agents (Dombrowski *et al.*, 1994, 1997). Within 1–2 years, the early-emerging glycogenotic foci gradually undergo metamorphosis towards a glycogen-poor, basophilic phenotype and give rise to hepatocellular adenomas and carcinomas, which regularly contain pancreatic islet cells. It may be relevant that an excess risk of primary liver cancer in human patients with diabetes mellitus has been repeatedly reported (Adami *et al.*, 1996; Moore *et al.*, 1998; Stuver, 1998); implications of the hyperinsulinaemia-diabetes-cancer link for preventive efforts have been considered (Moore *et al.*, 1998).

These observations and considerations prompted us to investigate the expression of several components of the insulin signalling cascade (Figure 2) in FAH that emerge in the stop model of chemical hepatocarcinogenesis. We chose to study the insulin-receptor (IR), the receptor of the insulin-like growth factor I (IGF-RI), the insulin

receptor substrates-1 and -2 (IRS-1, IRS-2) and the mitogen-activated extracellular signal-regulated kinase-1 (MEK-1) by immunohistochemistry (Nehrbass *et al.*, 1998, 1999; Nehrbass, 2000), and the proto-oncogenes *c-raf*-kinase and *c-myc* by *in situ* hybridization (Bannasch, 1996). The proto-oncogene *c-raf* holds a central position in several intracellular signalling cascades (Slupsky *et al.*, 1998). The product of the *c-myc* proto-oncogene acts as a transcription factor that, according to studies in transgenic mice, regulates hepatic glycolysis (Valera *et al.*, 1995). In early glycogenotic foci, all components of the insulin signalling cascade studied were upregulated, as demonstrated particularly convincingly for IRS-1, which is a multi-site docking protein acting as a principal intracellular substrate of the insulin receptor tyrosine kinase (Table 4). These findings suggest that activation of the insulin-stimulated raf-MAP kinase signal transduction pathway elicits preneoplastic hepatic glycogenesis (Nehrbass *et al.*, 1998, 1999). In hepadnaviral hepatocarcinogenesis, the insulinomimetic effect may also be responsible for the downregulation of expression of the viral surface antigen in glycogenotic FAH, as observed in HBV transgenic mice (Toshkov *et al.*, 1994), WHV-infected woodchucks (Bannasch *et al.*, 1995; Radaeva *et al.*, 2000) and human HBV carriers (Su *et al.*, 1998), since it has been shown in studies on a human hepatoma cell line that insulin may indeed suppress the expression of the surface antigen (Chou *et al.*, 1989). *In situ* investigations on the glycogenotic-basophilic cell lineage of human hepatocarcinogenesis have revealed that in HBV carriers, preneoplastic FAH of any type preferentially albeit rarely express the X protein of HBV, while p53 accumulation is invariably negative in FAH but correlates with neoplastic progression in HCC, irrespective of the risk factors involved in regions with low exposure to aflatoxins (Su *et al.*, 1998, 2000).

Progression-linked downregulation of insulin signalling during cellular dedifferentiation

As previously shown in experimental chemical hepatocarcinogenesis for the *c-raf*-kinase (Bannasch, 1996), the overexpression of most of the proteins of the insulin signalling cascade studied in the early glycogenotic cell populations presenting a high grade of differentiation is only

Table 4. Hormone-like effects of hepatocarcinogenic agents – I**Insulinomimetic effect elicits preneoplastic glycogenotic phenotype**

- Activation of insulin-signalling pathway: e.g. overexpression of insulin receptor, insulin-growth factor-I receptor, insulin receptor substrate-1, insulin receptor substrate-2, mitogen-activated extracellular signal-regulated kinase-1, and *c-raf*; increased synthesis of glycogen and/or fat; reduced activities of glucose-6-phosphatase and α -glucosidase; increased activity of glucose-6-phosphate dehydrogenase and cell proliferation
- Inactivation of glucagon-signalling pathway: e.g. reduced activities of adenylate cyclase and glycogen phosphorylase; increased liver type pyruvate kinase activity

Progression from preneoplastic glycogenotic to neoplastic basophilic phenotype

- Downregulation of insulin-signalling pathway
- Isoenzyme shift (e.g. glucokinase/hexokinase; liver type pyruvate kinase/fetal pyruvate kinase) stimulating glycolysis
- Further increase in pentose phosphate pathway (glucose-6-phosphate dehydrogenase) and cell proliferation
- Gradual reduction of gluconeogenesis and glycogenesis

transient, and is gradually downregulated during progression-linked dedifferentiation in later stages of hepatocarcinogenesis (Nehrbass *et al.*, 1998, 1999; Nehrbass, 2000). This event is closely related to the reduction in the glycogen initially stored in excess (Table 4), a further increase in the expression and activity of the key enzyme of the pentose phosphate pathway, elevation of cytoplasmic basophilia due to an increase in the number of ribosomes, and an ever-increasing cell proliferation and expression of *c-myc* (Bannasch, 1996; Bannasch *et al.*, 1997a). At about the same time, a shift from adult to fetal glycolytic isoenzymes, for example from glucokinase to hexokinase, and the liver-specific L-pyruvate kinase to the fetal M₂-pyruvate kinase takes place (Klimek & Bannasch, 1990, 1993; Hacker *et al.*, 1998; Steinberg *et al.*, 1999). In addition, the fetal glucose transporter protein GLUT1 emerges, while the earlier downregulation of the liver-specific adult glucose transporter protein GLUT2 is maintained (Grobholz *et al.*, 1993). This pronounced shift from anabolic to catabolic glucose metabolism is probably a prerequisite for a more effective energy supply favour-

ing the increase in cell proliferation. It remains to be clarified, however, by which growth factors cell proliferation is further stimulated when the insulin signalling pathway is downregulated. We have speculated that the relatively weak early proliferative stimulus mediated by insulin may be replaced by alternative growth factors (Nehrbass *et al.*, 1998), particularly IGF-II, which has been shown to be frequently overexpressed in late stages of hepatocarcinogenesis (Rogler *et al.*, 1995). Growth stimulation by IGF-II is preferentially or exclusively mediated by pathways that have not been completely clarified, but may stimulate cell proliferation without exerting insulinomimetic effects on glycogen metabolism.

Phenotypes mimicking responses to thyroid and ovarian hormones

In contrast to the glycogenotic foci, the preneoplastic amphophilic cell foci induced in rats by the peroxisome proliferator dehydroepiandrosterone are characterized by downregulation of IRS-1 and show a completely different histochemical pattern (Weber *et al.*, 1988; Mayer *et al.*, 1998a; Nehrbass *et al.*

al., 1999). Whereas a reduction in the activity of enzymes of glycogen metabolism is associated with an early loss of glycogen, the gluconeogenic enzyme glucose-6-phosphatase, several mitochondrial enzymes including cytochrome c oxidase and glycerol-3-phosphate dehydrogenase, and some peroxisomal enzymes are usually increased in their amount or activity (Table 5), suggesting a thyromimetic effect of dehydroepiandrosterone and other peroxisome proliferators (Bannasch *et al.*, 1997a; Mayer *et al.*, 1998a). A thyromimetic action of several peroxisome proliferators such as clofibrate and acetylsalicylic acid on rat liver, including changes in messenger RNA levels of certain genes involved in mitochondrial biogenesis has been reported (Cai *et al.*, 1996). In addition, a thyromimetic effect of peroxisome proliferators on the activities of several enzymes such as glycerol-3-phosphate dehydrogenase, malic enzyme and glucose-6-phosphatase has been found in rat liver homogenates and cultured hepatocytes (Hertz *et al.*, 1993, 1996).

In rodents, a number of the biological actions of peroxisome proliferators including dehydroepiandrosterone have been shown to be mediated by the peroxisome proliferator-activated receptor α (PPAR α), a member of the superfamily of nuclear steroid receptors (Green & Wahli, 1994; Schoongans *et al.*, 1997), which also mediate effects (possibly including peroxisome proliferation) of the thyroid hormone 3,3,5-triiodo-L-thyronine (T₃) (Francavilla *et al.*, 1994; Ledda-Columbano *et al.*, 1999). PPAR α is apparently responsible for peroxisome proliferation, activation of target genes encoding fatty acid-metaboliz-

ing enzymes, mitogenesis and ultimately hepatocarcinogenesis (Gonzalez *et al.*, 1998). In contrast to wild-type mice, PPAR α -null mice that were treated with a potent peroxisome proliferator developed neither hepatocellular neoplasms nor preneoplastic hepatocellular foci (Peters *et al.*, 1997). PPAR α is also required for gene induction by the less potent peroxisome proliferator dehydroepiandrosterone in mice (Peters *et al.*, 1996). However, according to Hertz and Bar-Tana (1998), the biological effects exerted by peroxisome proliferators in the human liver may be mediated by transduction pathways independent of PPAR α .

In the rat, the hypothesis of a thyromimetic effect of peroxisome proliferators eliciting the amphophilic preneoplastic phenotype has been substantiated by the recent observation of focal hyperproliferative hepatic lesions with a similar morphological and biochemical phenotype after intrahepatic thyroid tissue transplantation in thyroidectomized animals (Dombrowski *et al.*, 2000). Labeling of these rapidly emerging lesions with bromodeoxyuridine showed considerable proliferation within the transplants and in the surrounding amphophilic cell populations. Eighteen months after thyroid tissue transplantation, large amphophilic lesions were found, but frank hepatocellular neoplasms were not observed in this animal model. Hyperproliferative focal lesions resembling in some respects amphophilic cell foci were also induced in rat liver by intraportal transplantation of ovarian tissue in ovariectomized rats (Klotz *et al.*, 2000). In a preliminary long-term experiment, four of six animals developed hepato-

Table 5. Hormone-like effects of hepatocarcinogenic agents - II

Thyromimetic effect elicits preneoplastic amphophilic phenotype

- Downregulation of component (insulin receptor substrate-1) of insulin-signalling pathway
- Increased activity of glucose-6-phosphatase and glycogen loss
- Mitochondrial proliferation
- Increase in mitochondrial enzymes (glycerol-3-phosphate dehydrogenase, succinate dehydrogenase, cytochrome c oxidase) and malic enzyme

cellular neoplasms including three HCC, the phenotype of which was similar to that of the amphophilic-like FAH.

Although the glycogenotic and the amphophilic cell lineages are very different at first glance, there is circumstantial evidence from some experiments that they may transform into each other (Bannasch *et al.*, 1997a, Mayer *et al.*, 1998a; Radaeva *et al.*, 2000). This interconversion is difficult to understand, but crosstalk between two or several disturbed signal transduction pathways related to insulinomimetic or thyromimetic actions of the oncogenic agents might be involved.

Hepatic preneoplastic lesions as biomarkers in chemoprevention studies

Tissue specificity and phenotypic instability

The consistent development of preneoplastic FAH in all animal models of hepatocarcinogenesis and their apparent similarity in human hepatocarcinogenesis favour the use of these lesions as biomarkers in chemoprevention studies. A number of compounds such as several antioxidants (Thamavit *et al.*, 1985; Ito *et al.*, 1992) and oltipraz when administered to animals exposed to aflatoxin B₁ (Kensler *et al.*, 1987; Roebuck *et al.*, 1991) reduce the formation of both GST-P-positive FAH and HCC in rodents. However, some of the antioxidants (e.g., butylated hydroxyanisole, butylated hydroxytoluene) which inhibit carcinogenesis in the liver may enhance carcinogenesis at other sites (Imaida *et al.*, 1983; Ito *et al.*, 1988), indicating a possible limitation of preventive effects to certain target tissues. In addition, it is evident from the discussion in the preceding sections that preneoplastic FAH are neither uniform nor stable. Their phenotypic instability is an outstanding feature of their biological behaviour, be it related to progression or to reversion of neoplastic development. As discussed previously, the reversion-linked phenotypic instability of FAH may seriously hamper the interpretation of studies on carcinogenesis (Bannasch, 1986; Bannasch & Zerban, 1992). This may be even more critical in chemoprevention studies, since a reduction in the number and size of preneoplastic FAH inherent in the animal model used may be mistaken as a positive chemopreventive effect. Animal models largely avoiding this complication are available (Bannasch & Zerban, 1992, 1997).

The methods applied for identification of preneoplastic FAH in tissue sections are also critical in studies of both carcinogenesis and chemoprevention. Thus, the progression-linked phenotypic instability of FAH characterizing particularly the predominant glycogenotic-basophilic preneoplastic cell lineage implies that certain markers such as the activation of components of the insulin signalling cascade (e.g., IRS-1) are only useful for the detection of early-appearing FAH, while other markers such as cellular hyperproliferation and overexpression of *c-myc* or M₂-pyruvate kinase may only help to detect more advanced types of FAH and hepatocellular adenomas. Several of the standard markers used in many laboratories (e.g., glycogen, glucose-6-phosphate dehydrogenase, GSTP, γ GT) are suitable for the demonstration of a large proportion of FAH integrated into the glycogenotic-basophilic cell lineage, but largely or completely fail to show FAH with an amphophilic phenotype (Bannasch & Zerban, 1992, 1997; Mayer *et al.*, 1998a). There is not a single biochemical or molecular marker for all types of FAH. A number of comparative studies have clearly shown, however, that the vast majority of preneoplastic FAH are readily identifiable in H&E-stained tissue sections (complemented by serial sections treated with the PAS reagent in some specific cases) without any additional biochemical marker. The application of H&E-staining may be of particular advantage in chemoprevention studies, since both the morphological and the biochemical phenotype of FAH induced by hepatocarcinogens in a variety of rodent models is often modulated by additional exposure to other chemicals (Bannasch & Zerban, 1997).

Phenotypic modulation

In the context of chemoprevention, the phenotypic modulation produced by peroxisome proliferators is of special interest. Several peroxisome proliferators including nafenopin, clofibrate, ciprofibrate and dehydroepiandrosterone inhibit the expression of γ GT and GST-P, and cause a rapid loss of glycogen from glycogenotic FAH when given after DNA-reactive hepatocarcinogens (e.g., Numoto *et al.*, 1984; Hosokawa *et al.*, 1989; Gerbracht *et al.*, 1990; Tsuda *et al.*, 1992; Mayer *et al.*, 1998a). Gerbracht *et al.* (1990) emphasized that there was no increase in apoptosis within FAH

under these conditions, which might have been an alternative explanation for the reduction in the number and size of enzyme-altered foci. After additional administration of clofibrate to rats pretreated with *N*-nitrosodiethylamine, Hosokawa *et al.* (1989) found that FAH positive and negative for GST-P could be identified morphologically in H&E-stained sections. The total number of FAH, both positive and negative for GST-P, was higher in rats treated with *N*-nitrosodiethylamine followed by clofibrate than in those exposed to *N*-nitrosodiethylamine alone, indicating an enhancing rather than a reducing effect of clofibrate on the development of FAH. A higher incidence of hepatocellular carcinomas was also seen after additional treatment with clofibrate. An enhancing effect of nafenopin on rat hepatocarcinogenesis was found, although preneoplastic FAH were negative for γ GT and showed only low levels or absence of several GST isoenzymes (Grasl-Kraupp *et al.*, 1993a,b).

Dehydroepiandrosterone, which had been proposed as a possible chemopreventive agent because it inhibited the focal expression of GST-P in rat liver (Moore *et al.*, 1986; Garcea *et al.*, 1987), later turned out to be a complete hepatocarcinogen of the peroxisome proliferator type (Rao *et al.*, 1992; Hayashi *et al.*, 1994; Metzger *et al.*, 1995) and to enhance carcinogenesis in the liver (Metzger *et al.*, 1998) as well as in several other tissues (Feo *et al.*, 2000b). In Fischer-344 rats initiated with a single dose of *N*-nitrosodiethylamine, feeding a diet supplemented by the thyroid hormone T_3 led to a 70% reduction in the number of GST-P-positive FAH per cm^2 , although this hormone exerts strong mitogenic effects on the liver parenchyma (Ledda-Columbano *et al.*, 1999). This seems to indicate a chemopreventive potential of the thyroid hormone under these experimental conditions despite its mitogenic activity, since the authors found a 50% reduction in the incidence of HCC when similarly pretreated rats were exposed to seven cycles of T_3 -supplemented diet, as compared to rats undergoing the pretreatment procedure alone (Ledda-Columbano *et al.*, 2000). Green and black tea, the consumption of which has been shown to be associated with both negative and positive effects on human cancer incidence at various sites (Steele *et al.*, 2000), have been reported to induce hepatic peroxisome proliferation (Bu-Abbas *et al.*, 1999). Thus, it is conceivable that peroxi-

some proliferators, thyroid hormone and possibly other chemicals may exert both carcinogenic and chemopreventive effects on the liver parenchyma and other target tissues depending on the prevailing biological conditions and the dosing and time schedules employed.

Quantitative assessment of hepatic preneoplasia

The heterogeneity and instability of the phenotypic cellular changes that characterize FAH have serious implications for quantitative assessment (Pitot *et al.*, 1989; Schwarz *et al.*, 1989; Bannasch & Zerban, 1992). Using glycogen retention after starvation as a marker for FAH induced in rat liver by an initiation-promotion protocol, Kaufmann *et al.* (1985, 1987) estimated that only one carcinoma developed for every 1000 to 10 000 focal lesions that were observed concurrent with the appearance of neoplasms. Although this discrepancy may in part be a consequence of the experimental approach used, the large number of preneoplastic FAH implies a great advantage for the detection of early stages of neoplastic development in diagnostic pathology and interventional approaches for secondary prevention. The observations discussed in this review are not readily compatible with the mathematical standard multistage model of carcinogenesis based on the assumption of repeated clonal selections. Therefore, Kopp-Schneider *et al.* (1998) have elaborated a new mathematical model of hepatocarcinogenesis called the colour-shift model. In this model, phenotypic changes in focal hepatocellular lesions are treated as epigenetic events, possibly due to alterations in a number of cells from the very beginning, and progressing to hepatocellular carcinomas by changes running parallel in larger cell populations rather than repeated clonal selections as suggested by previous stereological studies on the dose- and time-dependence of the development of FAH in rats exposed to *N*-nitrosomorpholine (Enzmann & Bannasch, 1987; Weber & Bannasch, 1994a,b,c). Comparative investigations, in which the same morphometric data are being applied to both mathematical models, are under way and should help to further elucidate the sequence of cellular and molecular changes during hepatocarcinogenesis.

Depending on the dose and duration of the carcinogenic treatment, the lag period between the first appearance of FAH and neoplasms may vary

widely. In *N*-nitrosomorpholine-treated rats, lag periods for the occurrence of adenomas were between 15 and more than 50 weeks (Weber & Bannasch, 1994 a, b, c). There is at present no established marker which would permit us to predict precisely from the appearance of FAH at what time hepatocellular adenomas and carcinomas will develop. However, for many experimental situations, the assumption of a lag period of 6–12 months (about 15–30% of the average life span of the rat) seems to be reasonable. It is interesting to note that in relation to the average life span, these figures correspond closely to the 15–30 years which pass in the majority of children suffering from inborn hepatic glycogenosis type I until multiple hepatocellular neoplasms occur.

The main shortcoming of preneoplastic FAH for their use in early detection and secondary prevention of human HCC is the small size of the lesions and their location in an organ which is not easily accessible. Thus, most of the early preneoplastic FAH are smaller than a liver lobule, which has an average diameter of 1–2 mm in both rodents and humans. This small size precludes a non-invasive identification by any of the imaging procedures available at present. However, there is some hope that at least certain types of FAH can be diagnosed in patients by fine-needle biopsies. The further elucidation of the molecular and metabolic aberrations associated with neoplastic cell conversion in the liver should eventually provide a rational basis for early diagnosis, chemoprevention and, perhaps, also chemotherapy of HCC.

Acknowledgements

This work was supported by grant 0311834 from the Bundesministerium für Bildung und Forschung.

References

- Adami, H.O., Chow, W.H., Nyren, O., Berne, C., Linet, M.S., Ekblom, A., Wolk, A., McLaughlin, J.K. & Fraumeni, J.F., Jr (1996) Excess risk of primary liver cancer in patients with diabetes mellitus. *J. Natl Cancer Inst.*, **88**, 1472–1477
- Altmann, H.W. (1994) Hepatic neoforations. *Pathol. Res. Pract.*, **190**, 513–577
- Bannasch, P. (1968) The cytoplasm of hepatocytes during carcinogenesis. *Recent Results. Cancer Res.*, **19**, 1–100
- Bannasch, P. (1986) Preneoplastic lesions as end points in carcinogenicity testing. I. Hepatic preneoplasia. *Carcinogenesis*, **7**, 689–695
- Bannasch, P. (1996) Pathogenesis of hepatocellular carcinoma: sequential cellular, molecular, and metabolic changes. *Prog. Liver Dis.*, **14**, 161–197
- Bannasch, P. (1998) Evolution of liver cell cancer – interaction of viruses and chemicals. In: Deutsches Krebsforschungszentrum, ed., *Current Topics in Cancer Research*, New York, Springer, pp. 61–67
- Bannasch, P. & Schröder, C. (2001) Pathogenesis of primary liver tumours. In: MacSween, R.N.M., Anthony, P.P., Scheuer, P.J., Burt, T.A.D. & Portman, B.C., eds, *Pathology of the Liver*, New York, Churchill Livingstone (in press)
- Bannasch, P. & Zerban, H. (1992) Predictive value of hepatic preneoplastic lesions as indicators of carcinogenic response. In: Vainio, H., Magee, P.N., McGregor, D.B. & McMichael, A.J., eds, *Mechanisms of Carcinogenesis in Risk Identification*, Lyon, IARC, pp. 389–427
- Bannasch, P. & Zerban, H. (1997) Experimental chemical hepatocarcinogenesis. In: Okuda K. & Tabor E., eds, *Liver Cancer*, New York, Churchill Livingstone, pp. 213–253
- Bannasch, P., Hacker, H.J., Klimek, F. & Mayer, D. (1984) Hepatocellular glycogenesis and related pattern of enzymatic changes during hepatocarcinogenesis. *Adv. Enzyme Regul.*, **22**, 97–121
- Bannasch, P., Imani Koshkou, N., Hacker, H.J., Radaeva, S., Mrozek, M., Zillmann, U., Kopp-Schneider, A., Haberkorn, U., Elgas, M., Tolle, T., Roggendorf, M. & Toshkov, I. (1995) Synergistic hepatocarcinogenic effect of hepadnaviral infection and dietary aflatoxin B₁ in woodchucks. *Cancer Res.*, **55**, 3318–3330
- Bannasch, P., Klimek, F. & Mayer, D. (1997a) Early bioenergetic changes in hepatocarcinogenesis: preneoplastic phenotypes mimic responses to insulin and thyroid hormone. *J. Bioenerg. Biomemb.*, **29**, 303–313
- Bannasch, P., Jahn, U.-R., Hacker, H.J., Su, Q., Hofmann, W., Pichlmayr, R. & Otto, G. (1997b) Focal hepatic glycogenesis: a putative preneoplastic lesion associated with neoplasia and cirrhosis in explanted human livers. *Int. J. Oncol.*, **10**, 261–268
- Bianchi, L. (1993) Glycogen storage disease I and hepatocellular tumours. *Eur. J. Pediatr.*, **152** (Suppl. 1), S63–S70
- Bosch, F.X. (1997) Global epidemiology of hepatocellular carcinoma. In: Okuda K. & Tabor E., eds, *Liver Cancer*, New York, Churchill Livingstone, pp. 13–28

- Bu-Abbas, A., Dobrota, M., Copeland, E., Clifford, M.N., Walker, R. & Ioannides, C. (1999) Proliferation of hepatic peroxisomes in rats following the intake of green or black tea. *Toxicol. Lett.*, **109**, 69–76
- Cai, Y., Nelson, B.D., Li, R., Luciaková, K. & DePierre, J.W. (1996) Thyromimetic action of the peroxisome proliferators clofibrate, perfluorooctanoic acid, and acetylsalicylic acid includes changes in mRNA levels for certain genes involved in mitochondrial biogenesis. *Arch. Biochem. Biophys.*, **325**, 107–112
- Chang, M.-H., Chen, C.-J., Lai, M.-S., Hsu, H.-M., Wu, T.-C., Kong, M.-S., Liang, D.-C., Shau, W.-Y. & Chen, D.-S. (1997) Universal hepatitis B vaccination in Taiwan and the incidence of hepatocellular carcinoma in children. *New Engl. J. Med.*, **336**, 1855–1859
- Chou, C.-K., Su, T.-S., Chang, C.-P., Hu, C., Huang, M.-Y., Suen, C.-S., Chou, N.-W. & Ting, L.-P. (1989) Insulin suppresses hepatitis B surface antigen expression in human hepatoma cells. *J. Biol. Chem.*, **264**, 15304–15308
- Christensen, J.G., Romach, E.H., Healy, L.N., Gonzales, A., Anderson, S.P., Malarkey, D.E., Corton, J.C., Fox, T.R., Cattley, R.C. & Goldsworthy, T.L. (1999) Altered bcl-2 family expression during non-genotoxic hepatocarcinogenesis in mice. *Carcinogenesis*, **20**, 1583–1590
- Deugnier, Y.M., Charalambous, P., Le Quilleuc, D., Turlin, B., Searle, J., Brissot, P., Powell, L.W. & Halliday, J.W. (1993) Preneoplastic significance of hepatic iron-free foci in genetic hemochromatosis: a study of 185 patients. *Hepatology*, **18**, 1363–1369
- Dombrowski, F., Lehringer-Polzin, M. & Pfeifer, U. (1994) Hyperproliferative liver acini after intraportal islet transplantation in streptozotocin-induced diabetic rats. *Lab. Invest.*, **71**, 688–699
- Dombrowski, F., Bannasch, P. & Pfeifer, U. (1997) Hepatocellular neoplasms induced by low-number pancreatic islet transplants in streptozotocin diabetic rats. *Am. J. Pathol.*, **150**, 1071–1087
- Dombrowski, F., Klotz, L., Hacker, H.J., Li, Y., Klingmüller, D., Brix, K., Herzog, V. & Bannasch, P. (2000) Hyperproliferative hepatocellular alterations after intra-portal transplantation of thyroid follicles. *Am. J. Pathol.*, **156**, 99–113
- Enzmann, H. & Bannasch, P. (1987) Potential significance of phenotypic heterogeneity of focal lesions at different stages in hepatocarcinogenesis. *Carcinogenesis*, **8**, 1607–1612
- Farber, E. (1996) The step-by-step development of epithelial cancer: from phenotype to genotype. *Adv. Cancer Res.*, **70**, 21–48
- Farber, E. & Sarma, D.S. (1987) Hepatocarcinogenesis: a dynamic cellular perspective. *Lab. Invest.*, **56**, 4–22
- Feo, F., Pascale, R.M., Simile, M.M., De Miglio, M.R., Muroli, M.R. & Calvisi, D. (2000a) Genetic alterations in liver carcinogenesis: implications for new preventive and therapeutic strategies. *Crit. Rev. Oncogenesis*, **11**, 19–62
- Feo, F., Pascale, R.M., Simile, R.M. & De Miglio, M.R. (2000b) Role of dehydroepiandrosterone in experimental and human carcinogenesis. In: Kalimi, M. & Regelson, W., eds, *Dehydroepiandrosterone (DHEA)*, Berlin, de Gruyter, pp. 215–236
- Francavilla, A., Carr, B.I., Azzarone, A., Polimeno, L., Wang, Z., Van Thiel, D.H., Subbotin, V., Prelich, J.G. & Starzl, T.E. (1994) Hepatocyte proliferation and gene expression induced by triiodothyronine *in vivo* and *in vitro*. *Hepatology*, **20**, 1237–1241
- Friedrich-Freksa, H., Papadopulu, G. & Gössner, W. (1969) Histochemische Untersuchungen der Cancergene in der Rattenleber nach zeitlich begrenzter Verabfolgung von Diethylnitrosamin. *Z. Krebsforsch.*, **72**, 240–253
- Garcea, R., Daino, L., Pascale, R.M., Frassetto, S., Cozzolino, P., Ruggiu, M.E. & Feo, F. (1987) Inhibition by dehydroepiandrosterone of liver preneoplastic foci formation in rats after initiation-selection in experimental carcinogenesis. *Toxicol. Pathol.*, **15**, 164–168
- Gerbracht, U., Bursch, W., Kraus, P., Putz, B., Reinacher, M., Zimmermann-Trosiener, I. & Schulte-Hermann, R. (1990) Effects of hypolipidemic drugs nafenopin and clofibrate on phenotypic expression and cell death (apoptosis) in altered foci of rat liver. *Carcinogenesis*, **11**, 617–624
- Gonzalez, F.J., Peters, J.M. & Cattley, R. (1998) Mechanism of action of nongenotoxic peroxisome proliferators: role of the peroxisome proliferator-activated receptor α . *J. Natl Cancer Inst.*, **90**, 1702–1709
- Goodman, D.G., Maronpot, R.R., Newberne, P.M., Popp, J.A. & Squire, R.A. (1994) Proliferative and selected lesions in the liver of rats. In: Street, C.S., Burek, J.D., Hardisty, J.F., Garner, F.M., Leininger, J.R., Pletscher, J.M. & Moch, R.W., eds, *Guides for Toxicologic Pathology*, Washington, Society of Toxicologic Pathologists/American Registry of Pathology/Armed Forces Institute of Pathology, pp. G1-5, 1–24
- Grasl-Kraupp, B., Huber, W., Just, W., Gibson, G. & Schulte-Hermann, R. (1993a) Enhancement of peroxisomal enzymes, cytochrome P-452 and DNA synthesis in putative preneoplastic foci of rat liver treated with the peroxisome proliferator nafenopin. *Carcinogenesis*, **14**, 1007–1012

- Grasl-Kraupp, B., Waldhör, T., Huber, W. & Schulte-Hermann, R. (1993b) Glutathione S-transferase isoenzyme patterns in different subtypes of enzyme-altered rat liver foci treated with the peroxisome proliferator nafenopin or with phenobarbital. *Carcinogenesis*, **14**, 2407–2412
- Green, S. & Wahli, W. (1994) Peroxisome proliferator-activated receptors: finding the orphan a home. *Mol. Cell. Endocrinol.*, **100**, 149–153
- Grisham, J.W. (1996) Interspecies comparison of liver carcinogenesis: implications for cancer risk assessment. *Carcinogenesis*, **18**, 59–81
- Grobholz, R., Hacker, H.J., Thorens, B. & Bannasch, P. (1993) Reduction in the expression of glucose transporter protein GLUT2 in preneoplastic and neoplastic hepatic lesions and reexpression of GLUT1 in late stages of hepatocarcinogenesis. *Cancer Res.*, **53**, 4204–4211
- Hacker, H.J., Moore, M.A., Mayer, D. & Bannasch, P. (1982) Correlative histochemistry of some enzymes of carbohydrate metabolism in preneoplastic and neoplastic lesions in the rat liver. *Carcinogenesis*, **3**, 1265–1272
- Hacker, H.J., Steinberg, P. & Bannasch, P. (1998) Pyruvate kinase isoenzyme shift from L-type to M₂-type is a late event in hepatocarcinogenesis induced in rats by a choline-deficient/D,L-ethionine-supplemented diet. *Carcinogenesis*, **19**, 99–107
- Harada, T., Maronpot, R.R., Morris, R.W. & Boorman, G.A. (1989) Observations on altered hepatocellular foci in National Toxicology Program two-year carcinogenicity studies in rats. *Toxicol. Pathol.*, **17**, 690–708
- Hasegawa, R. & Ito, N. (1994) Hepatocarcinogenesis in the rat. In: Waalkes, M.P. & Ward, J.M., eds, *Carcinogenesis*, New York, Raven, pp. 39–65
- Hayashi, F., Tamura, H., Yamada, J., Kasai, H. & Suga, T. (1994) Characteristics of the hepatocarcinogenesis caused by dehydroepiandrosterone, a peroxisome proliferator, in male F-344 rats. *Carcinogenesis*, **15**, 2215–2219
- Hertz, R. & Bar-Tana, J. (1998) Peroxisome proliferator-activated receptor (PPAR) alpha activation and its consequences in humans. *Toxicol. Lett.*, **102–103**, 85–90
- Hertz, R., Kalderon, B. & Bar-Tana, J. (1993) Thyromimetic effect of peroxisome proliferators. *Biochimie*, **75**, 257–261
- Hertz, R., Nikodem, V., Ben-Ishai, A., Berman, I. & Bar-Tana, J. (1996) Thyromimetic mode of action of peroxisome proliferators: activation of "malic" enzyme gene transcription. *Biochem. J.*, **319**, 241–248
- Hosokawa, S., Tatematsu, M., Aoki, T., Nakanowatari, J., Igarashi, T. & Ito, N. (1989) Modulation of diethylnitrosamine-initiated placental glutathione positive preneoplastic and neoplastic lesions by clofibrate, a hepatic peroxisome proliferator. *Carcinogenesis*, **10**, 2237–2241
- Imaida, K., Fukushima, S., Shirai, T., Ohtani, M., Nakanishi, K. & Ito, N. (1983) Promoting activities of butylated hydroxyanisole and butylated hydroxytoluene on 2-stage urinary bladder carcinogenesis and inhibition of γ -glutamyltranspeptidase-positive foci development in the liver of rats. *Carcinogenesis*, **4**, 895–899
- Ito, N., Tsuda, H., Hasegawa, R., Tatematsu, M., Imaida, K. & Asamoto, M. (1988) Medium-term bioassays for environmental carcinogens – two-step liver and multi-organ carcinogenesis protocols. In: Travis, C.C., ed., *Biologically Based Methods for Cancer Risk Assessment*, New York, London, Plenum, pp. 209–230
- Ito, N., Shirai, T. & Hasegawa, R. (1992) Medium-term bioassays for carcinogens. In: Vainio, H., Magee, P.N., McGregor, D.B. & McMichael, A.J., eds, *Mechanisms of Carcinogenesis in Risk Identification*, Lyon, IARC, pp. 353–388
- Ito, N., Imaida, K., Tamano, S., Hagiwara, A. & Shirai, T. (1998) Medium-term bioassays as alternative carcinogenicity tests. *J. Toxicol. Sci.*, **23**, 103–106
- Kalengayi, M.M.R., Ronchi, G. & Desmet, V.J. (1975) Histochemistry of gamma-glutamyl transpeptidase in rat liver during aflatoxin B₁-induced carcinogenesis. *J. Natl Cancer Inst.*, **55**, 579–588
- Kaufmann, W.K., MacKenzie, S.A. & Kaufman, D.G. (1985) Quantitative relationship between hepatocytic neoplasms and islands of cellular alteration during hepatocarcinogenesis in the male F344 rat. *Am. J. Pathol.*, **119**, 171–174
- Kaufmann, W.K., Rahija, R.J., MacKenzie, S.A. & Kaufman, D.G. (1987) Cell cycle-dependent initiation of hepatocarcinogenesis in rats by (\pm) 7 α , 8 α -dihydroxy-9 α , 10 α -epoxy-7,8,9,10-tetrahydrobenzo(a)pyrene. *Cancer Res.*, **47**, 3771–3775
- Kensler, T.W., Egner, P.A., Dolan, P.M., Groopman, J.D. & Roebuck, B.D. (1987) Mechanism of protection against aflatoxin tumorigenicity in rats fed 5-(2-pyrazinyl)-4-methyl-1,2-dithiol-3-thione (oltipraz) and related 1,2-dithiol-3-thiones and 1,2-dithiol-3-ones. *Cancer Res.*, **47**, 4271–4277
- Kim, C.M., Koike, K., Saito, J., Miyamura, T. & Jay, G. (1991) HBx gene of hepatitis B virus induces liver cancer in transgenic mice. *Nature*, **351**, 317–320
- Kitten, O. & Ferry, N. (1998) Mature hepatocytes actively divide and express gamma-glutamyl transpeptidase after D-galactosamine liver injury. *Liver*, **18**, 398–404

- Klimek, F. & Bannasch, P. (1990) Biochemical microanalysis of pyruvate kinase activity in preneoplastic and neoplastic liver lesions induced in rat by N-nitrosomorpholine. *Carcinogenesis*, **11**, 1377-1380
- Klimek, F. & Bannasch, P. (1993) Isoenzyme shift from glucokinase to hexokinase is not an early but a late event in hepatocarcinogenesis. *Carcinogenesis*, **14**, 1857-1861
- Klimek, F., Mayer, D. & Bannasch, P. (1984) Biochemical microanalysis of glycogen content and glucose-6-phosphate dehydrogenase activity in focal lesions of the rat liver induced by N-nitrosomorpholine. *Carcinogenesis*, **5**, 265-268
- Klotz, L., Hacker, H.J., Klingmüller, D., Bannasch, P., Pfeifer, U. & Dombrowski, F. (2000) Hepatocellular alterations after intraportal transplantation of ovarian tissue in ovariectomized rats. *Am. J. Pathol.*, **156**, 1613-1626
- Kopp-Schneider, A., Portier, C. & Bannasch, P. (1998) A model for hepatocarcinogenesis treating phenotypical changes in focal hepatocellular lesions as epigenetic events. *Math. Biosci.*, **148**, 181-204
- Lazaro, C.A., Rhim, J.A., Yamada, Y. & Fausto, N. (1998) Generation of hepatocytes from oval cell precursors in culture. *Cancer Res.*, **58**, 5514-5522
- Ledda-Columbano, G.M., Perra, A., Piga, R., Pibini, M., Loi, R., Shinozuka, H. & Columbano, A. (1999) Cell proliferation induced by 3,3,5-triiodo-L-thyronine is associated with a reduction in the number of preneoplastic hepatic lesions. *Carcinogenesis*, **20**, 2299-2304
- Ledda-Columbano, G.M., Perra, A., Loi, R., Shinozuka, H. & Columbano, A. (2000) Cell proliferation induced by triiodo-thyronine in rat liver is associated with nodule regression and reduction of hepatocellular carcinomas. *Cancer Res.*, **60**, 603-609
- Marsman, S.D. & Popp, J.A. (1994) Biological potential of basophilic hepatocellular foci and hepatic adenoma induced by the peroxisome proliferator, Wy-14,643. *Carcinogenesis*, **15**, 111-117
- Mayer, D., Metzger, C., Leonetti, P., Beier, K., Benner, A. & Bannasch, P. (1998a) Differential expression of key enzymes of energy metabolism in preneoplastic and neoplastic rat liver lesions induced by N-nitrosomorpholine and dehydroepiandrosterone. *Int. J. Cancer (Pred. Oncol.)*, **79**, 232-240
- Mayer, D., Klimek, F. & Bannasch, P. (1998b) Cytochemical and biochemical studies on adenylate cyclase activity in preneoplastic and neoplastic liver tissue and cultured liver cells. *Microsc. Res. Technol.*, **40**, 463-472
- Metzger, C., Mayer, D., Hoffmann, H., Bocker, T., Hobe, G., Benner, A. & Bannasch, P. (1995) Sequential appearance and ultrastructure of amphiphilic cell foci, adenomas and carcinomas in the liver of male and female rats treated with dehydroepiandrosterone (DHEA). *Toxicol. Pathol.*, **23**, 591-605
- Metzger, C., Bannasch, P. & Mayer, D. (1998) Enhancement and phenotypic modulation of N-nitrosomorpholine-induced hepatocarcinogenesis by dehydroepiandrosterone. *Cancer Lett.*, **121**, 125-131
- Montesano, R., Hainaut, P. & Wild, C.P. (1997) Hepatocellular carcinoma: from gene to public health. *J. Natl Cancer Inst.*, **89**, 1844-1851
- Moore, M.A. & Kitagawa, T. (1986) Hepatocarcinogenesis in the rat: the effect of the promoters and carcinogens in vivo and in vitro. *Int. Rev. Cytol.*, **101**, 125-173
- Moore, M.A., Thamavit, N., Tsuda, H., Sato, K., Ichira, A. & Ito, N. (1986) Modifying influence of dehydroepiandrosterone on the development of dihydroxy-din-propylnitrosamine-initiated lesions in the thyroid, lung and liver of F344 rats. *Carcinogenesis*, **7**, 311-316
- Moore, M.A., Park, C.B. & Tsuda, H. (1998) Implications of hyperinsulinaemia-diabetes-cancer link for preventive efforts. *Eur. J. Cancer Prev.*, **7**, 89-107
- Nehrbass, D. (2000) *Veränderungen in der Insulin-Signaltransduktionskaskade während der Hepatocarcinogenese der Ratte*. University of Giessen, Thesis
- Nehrbass, D., Klimek, F. & Bannasch, P. (1998) Overexpression of insulin receptor substrate-1 emerges early in hepatocarcinogenesis and elicits preneoplastic hepatic glycogenesis. *Am. J. Pathol.*, **152**, 341-345
- Nehrbass, D., Klimek, F., Bannasch, P. & Mayer, D. (1999) Insulin receptor substrate-1 is over-expressed in cytogenetic but not in amphiphilic preneoplastic hepatic foci induced in rats by N-nitrosomorpholine and dehydroepiandrosterone. *Cancer Lett.*, **140**, 75-79
- Numoto, S., Furukawa, K., Furuya, K. & Williams, G.M. (1984) Effects of the hepatocarcinogenic peroxisome-proliferating hypolipidemic agents clofibrate and nafenopin on the rat liver cell membrane enzymes gamma-glutamyl transpeptidase and alkaline phosphatase and on the early stages of liver carcinogenesis. *Carcinogenesis*, **5**, 1603-1611
- Ober, S., Zerban, H., Spiethoff, A., Wegener, K., Schwarz, M. & Bannasch, P. (1994) Preneoplastic foci of altered hepatocytes induced in rats by irradiation with α -particles of Thorotrast and neutrons. *Cancer Lett.*, **83**, 81-88
- Oehlert, W. (1978) Radiation-induced liver cell carcinoma in the rat. In: Remmer, H., Bolt, H.M., Bannasch, P. & Popper, H., eds, *Primary Liver Tumors*, Lancaster, MTP, pp. 217-225

- Okuda, K. & Tabor, E., eds (1997) *Liver Cancer*, New York, Churchill Livingstone
- Peters, J.M., Zhou, Y.C., Ram, P.A., Lee, S.S.T., Gonzalez, F.J. & Waxman, D.J. (1996) Peroxisome proliferator-activated receptor alpha required for gene induction by dehydroepiandrosterone-3 beta-sulfate. *Mol. Pharmacol.*, **50**, 67-74
- Peters, J.M., Cattley, R.C. & Gonzalez, F.J. (1997) Role of PPAR alpha in the mechanism of action of the nongenotoxic carcinogen and peroxisome proliferator Wy-14,643. *Carcinogenesis*, **18**, 2029-2033
- Pitot, H.C. (1990) Altered hepatic foci: their role in murine hepatocarcinogenesis. *Ann. Rev. Pharmacol. Toxicol.*, **30**, 465-500
- Pitot, H.C. & Dragan, Y.P. (1994) Chemical induction of hepatic neoplasia. In: Fausto, N., Jakoby, W.B. & Schachter, D.A., eds, *The Liver, Biology and Pathobiology*, 3rd Ed., New York, Raven, pp. 1467-1495
- Pitot, H.C., Campbell, H.A., Maronpot, R., Bawa, N., Rizvi, T.A., Xu, Y.-H., Sargent, L., Dragan, Y. & Pyron, M. (1989) Critical parameters in the quantitation of the stages of initiation, promotion, and progression in one model of hepatocarcinogenesis in the rat. *Toxicol. Pathol.*, **17**, 594-612
- Radaeva, S., Li, Y., Hacker, H.J., Burger, V., Kopp-Schneider, A. & Bannasch, P. (2000) Hepadnaviral hepatocarcinogenesis: *in situ* visualization of viral antigens, cytoplasmic compartmentation, enzymic patterns, and cellular proliferation in preneoplastic hepatocellular lineages in woodchucks. *J. Hepatol.*, **33**, 580-600
- Rao, M.S., Lalwani, N.D., Scarpelli, D.G. & Reddy, J.K. (1982) The absence of γ -glutamyltranspeptidase activity in putative preneoplastic lesions and in hepatocellular carcinomas induced in rats by the hypolipidemic peroxisome proliferator Wy-14,643. *Carcinogenesis*, **3**, 1231-1233
- Rao, M.S., Subbaro, V., Yeldani, A.V. & Reddy, J.K. (1992) Hepatocarcinogenicity of dehydroepiandrosterone in the rat. *Cancer Res.*, **52**, 2977-2979
- Roebuck, B.D., Liu, Y.-L., Rogers, A.E., Groopman, J.D. & Kensler, W. (1991) Protection against aflatoxin B₁-induced hepatocarcinogenesis in F344 rats by 5-(2-pyrazinyl)-4-methyl-1,2-dithiole-3-thione (oltipraz): predictive role for short-term molecular dosimetry. *Cancer Res.*, **51**, 5501-5506
- Rogler, C.E., Rogler, L.E., Yang, D., Breiteneder-Geleef, S., Gong, S. & Wang H. (1995) Contributions of hepadnavirus research to our understanding of hepatocarcinogenesis. In: Jirtle, R.L., ed., *Liver Regeneration and Carcinogenesis*, San Diego, Academic Press, pp. 113-140
- Sato, K. (1989) Glutathione transferases as markers of preneoplasia and neoplasia. *Adv. Cancer Res.*, **52**, 205-255
- Sato, K., Kitahara, A., Satoh, K., Ishikawa, T., Tatematsu, M. & Ito, N. (1984) The placental form of glutathione S-transferase as a new marker protein for preneoplasia in rat chemical carcinogenesis. *Gann*, **75**, 199-202
- Schoongans, K., Martin, G., Staels, B. & Auwerx, J. (1997) Peroxisome proliferator-activated receptors, orphans with ligands and function. *Curr. Opin. Lipidol.*, **8**, 159-166
- Schwarz, M., Buchmann, A., Schulte, M., Pearson, D. & Kunz, W. (1989) Heterogeneity of enzyme-altered foci in rat liver. *Toxicol. Lett.*, **49**, 297-317
- Slupsky, J.R., Weber, C.K., Ludwig, S. & Rapp, U.R. (1998) Raf-dependent signaling pathways in cell growth and differentiation. In: Bannasch, P., Kanduc, D., Papa, S. & Tager, J.M., eds, *Cell Growth and Oncogenesis*, Basel, Birkhäuser, pp. 75-95
- Steele, V.E., Kelloff, G.J., Balentine, D., Boone, C.W., Mehta, R., Bagheri, D., Sigman, C.C., Zhu, S. & Sharma, S. (2000) Comparative chemopreventive mechanisms of green tea, black tea and selected polyphenol extracts measured by *in vitro* bioassays. *Carcinogenesis*, **21**, 63-67
- Steinberg, P., Klingelhöffer, A., Schäfer, A., Wüst, G., Weiße, G., Oesch, F. & Eigenbrodt, E. (1999) Expression of pyruvate kinase M₂ in preneoplastic hepatic foci of N-nitroso-morpholine-treated rats. *Virchows Arch.*, **434**, 213-220
- Ströbel, P., Klimek, F., Kopp-Schneider, A. & Bannasch, P. (1998) Xenomorphic hepatocellular precursors and neoplastic progression of tigroid cell foci induced in rats with low doses of N-nitrosomorpholine. *Carcinogenesis*, **19**, 2069-2080
- Stuver, S.O. (1998) Towards global control of liver cancer. *Seminars Cancer Biol.*, **18**, 299-306
- Su, Q., Benner, A., Hofmann, W.J., Otto, G., Pichlmayr, R. & Bannasch, P. (1997) Human hepatic preneoplasia: phenotypes and proliferation kinetics of foci and nodules of altered hepatocytes and their relationship to liver cell dysplasia. *Virchows Arch.*, **431**, 391-406
- Su, Q., Schröder, C.H., Hofmann, W.J., Otto, G., Pichlmayr, R. & Bannasch, P. (1998) Expression of hepatitis B virus X protein in HBV-infected human livers and hepatocellular carcinomas. *Hepatology*, **26**, 1109-1120
- Su, Q., Schröder, C.H., Otto, G. & Bannasch, P. (2000) Overexpression of p53 is not directly related to hepatitis B x protein expression and is associated with neoplastic progression rather than hepatic preneoplasia. *Mutation Res.*, **462**, 365-380

- Thamavit, W., Tatematsu, M., Ogiso, T., Mera, Y., Tsuda, H. & Ito, N. (1985) Dose-dependent effects of butylated hydroxyanisole, butylated hydroxytoluene, and ethoxyquin in induction of foci of rat liver cells containing the placental form of glutathione S-transferase. *Cancer Lett.*, **27**, 295-305
- Toshkov, I., Hacker, H.J., Roggendorf, M. & Bannasch, P. (1990) Phenotypic patterns of preneoplastic and neoplastic hepatic lesions in woodchucks infected with woodchuck hepatitis virus. *J. Cancer Res. Clin. Oncol.*, **116**, 581-90.
- Toshkov, I., Chisari, F.V. & Bannasch, P. (1994) Hepatic preneoplasia in hepatitis B virus transgenic mice. *Hepatology*, **20**, 1162-1172
- Tsuda, H., Ozaki, K., Uwagawa, S., Yamaguchi, S., Hakoi, K., Aoki, T., Kato, T., Sato, K. & Ito, N. (1992) Effects of modifying agents on conformity of enzyme phenotype and proliferative potential in focal preneoplastic and neoplastic liver cell lesions in rats. *Jpn. J. Cancer Res.*, **83**, 1154-1165
- US National Institute of Environmental Health Sciences (1989) Significance of foci of cellular alteration. A symposium. *Toxicol. Pathol.*, **17**, 557-735
- Valera, A., Pujol, A., Gregori, X., Riu, E., Visa, J. & Bosch, F. (1995) Evidence from transgenic mice that myc regulates hepatic glycolysis. *FASEB J.*, **9**, 1067-1078
- Weber, E. & Bannasch P. (1994a) Dose and time dependence of the cellular phenotype in rat hepatic preneoplasia and neoplasia induced by single oral exposures to N-nitrosomorpholine. *Carcinogenesis*, **15**, 1219-1226
- Weber, E. & Bannasch, P. (1994b) Dose and time dependence of the cellular phenotype in rat hepatic preneoplasia and neoplasia induced in stop experiments by oral exposure to N-nitroso-morpholine. *Carcinogenesis*, **15**, 1227-1234
- Weber, E. & Bannasch, P. (1994c) Dose and time dependence of the cellular phenotype in rat hepatic preneoplasia and neoplasia induced by continuous oral exposure to N-nitroso-morpholine. *Carcinogenesis*, **15**, 1235-1242
- Weber, E., Moore, M.A. & Bannasch, P. (1988) Enzyme histochemical and morphological phenotype of amphophilic foci and amphophilic/tigroid cell neoplastic nodules in rat liver after combined treatment with dehydroepiandrosterone and N-nitrosomorpholine. *Carcinogenesis*, **9**, 1049-1054
- Williams, G.M. & Enzmann, H. (1998) The rat liver hepatocellular-altered focus-limited bioassay for chemicals with carcinogenic activity. In: Kitten, K.T., ed., *Carcinogenicity*, New York, Marcel Dekker, pp. 361-394
- Williams, G.M., Klaiber, M., Parker, S.E. & Farber, E. (1976) Nature of early appearing carcinogen-induced liver lesions resistant to iron accumulation. *J. Natl Cancer Inst.*, **57**, 157-165
- Zerban, H., Radig, S., Kopp-Schneider, A. & Bannasch, P. (1994) Cell proliferation and cell death (apoptosis) in hepatic preneoplasia and neoplasia are closely related to phenotypic cellular diversity and instability. *Carcinogenesis*, **15**, 2467-2473

Corresponding author:

P. Bannasch

Division of Cell Pathology - C0100
Deutsches Krebsforschungszentrum
Im Neuenheimer Feld 280
69120 Heidelberg,
Germany