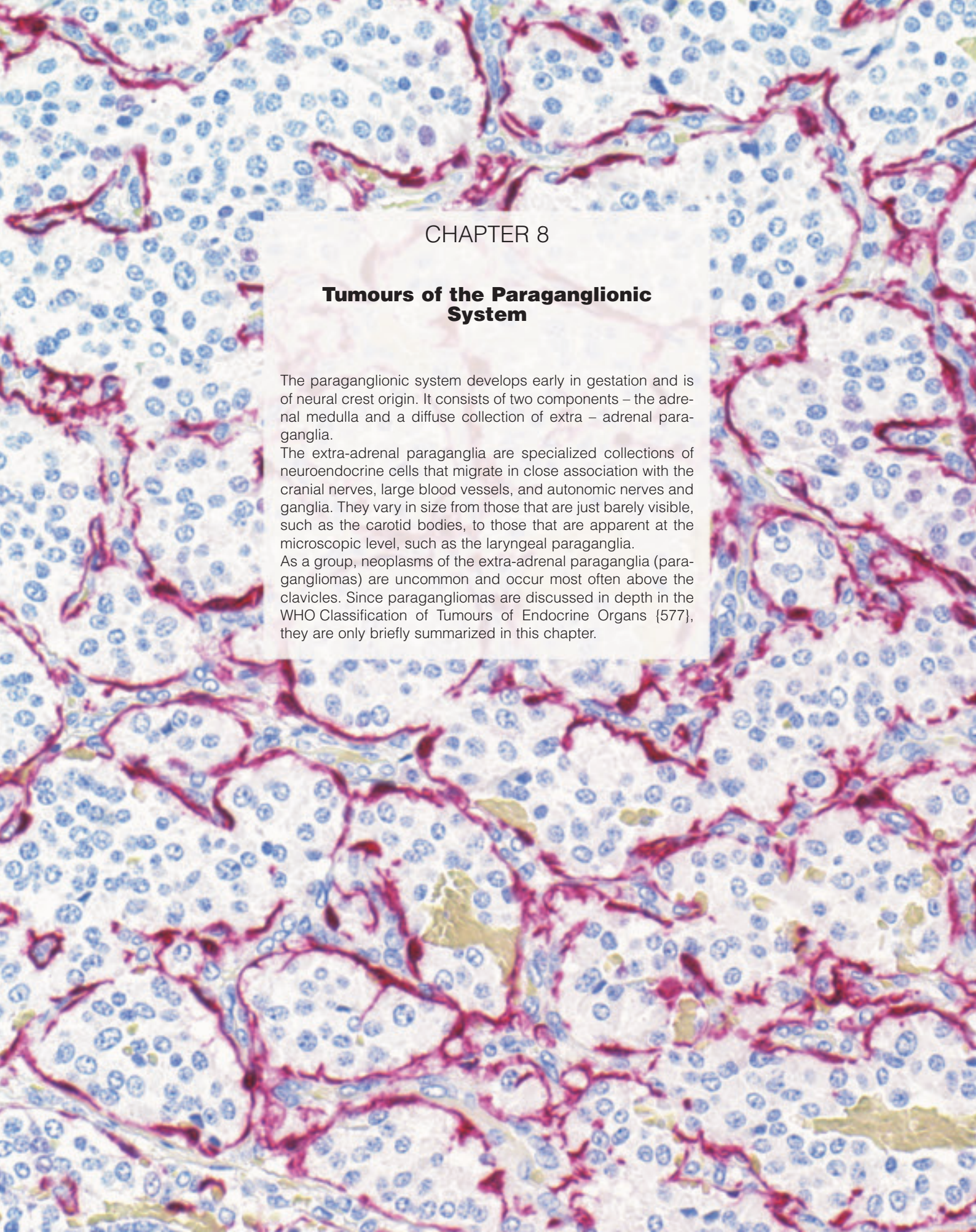

CHAPTER 8

Tumours of the Paraganglionic System

The paraganglionic system develops early in gestation and is of neural crest origin. It consists of two components – the adrenal medulla and a diffuse collection of extra – adrenal paraganglia.

The extra-adrenal paraganglia are specialized collections of neuroendocrine cells that migrate in close association with the cranial nerves, large blood vessels, and autonomic nerves and ganglia. They vary in size from those that are just barely visible, such as the carotid bodies, to those that are apparent at the microscopic level, such as the laryngeal paraganglia.

As a group, neoplasms of the extra-adrenal paraganglia (paragangliomas) are uncommon and occur most often above the clavicles. Since paragangliomas are discussed in depth in the WHO Classification of Tumours of Endocrine Organs {577}, they are only briefly summarized in this chapter.

Tumours of the paraganglionic system: Introduction

L. Barnes
L.L.Y. Tse
J.L. Hunt
L. Michaels

Introduction

The extra-adrenal paraganglia can be divided into sympathetic and parasympathetic types. Although they are indistinguishable at the cellular level, they differ in their anatomic distribution and secretory products The sympathetic paraganglia are found primarily in the axial regions of the trunk along the prevertebral and paravertebral sympathetic chains and in connective tissue in or near pelvic organs. In contrast, parasympathetic paraganglia are localized almost exclusively in the head and neck along the branches of the glossopharyngeal and vagus nerves.

Although both types of paraganglia produce catecholamines, clinical signs of excess production are usually associated with those that are of sympathetic origin. Tumours associated with significant amounts of epinephrine (adrenaline) are almost always of sympathetic origin. Those lesions that occur in patients with hypoxemia, in contrast, are typically parasympathetic in origin. Overlaps in secretory expression, however, do occur. Parasympathetic paragangliomas, in contrast to their sympathetic counterparts, are also more often familial and less likely to be malignant Paragangliomas of the head and neck are found primarily at the bifurcation of the common carotid artery, in the middle ear – temporal bone, along the course of the vagus nerve, and exceptionally, in the orbit, nasal cavity, paranasal sinuses, nasopharynx, larynx, trachea and thyroid.

Table 8.1 WHO Classification and ICD-O codes of paragangliomas of the head and neck region. For paragangliomas outside the head and neck region, see WHO Classification of Tumours of Endocrine Organs {577}.

Carotid body paraganglioma	8692/1
Jugulotympanic paraganglioma	8690/1
Vagal paraganglioma	8693/1
Laryngeal paraganglioma	8693/1
Miscellaneous paragangliomas	8693/1

[1] Morphology code of the International Classification of Diseases for Oncology (ICD-O) {821} and the Systematized Nomenclature of Medicine (http://snomed.org). Behaviour is coded /0 for benign tumours, /3 for malignant tumours, and /1 for borderline or uncertain behaviour.

Table 8.2 Classification of paraganglia and their main secretory products.

Paraganglion	Secretion
1. Adrenal medulla	80% epinephrine (adrenaline)
2. Extra-adrenal	
Sympathetic	90% norepinephrine (noradrenaline)
Parasympathetic	Dopamine

Table 8.3 Comparison of sympathetic and parasympathetic paragangliomas.

Feature	Sympathetic	Parasympathetic
Location	Abdomen	Head and Neck
Functional status	Occasional	Uncommon
Familial history	Uncommon	Common
Malignancy	14-50%*	1-13%*

*Varies according to site of origin of the paraganglioma.

Anatomy

Carotid body paraganglia

Carotid body paraganglia are paired, bilateral, usually symmetrical aggregates of specialized neuroendocrine tissue located at the bifurcation of the common carotid artery along its posteromedial wall, either within or immediately external to the adventitia. They are anchored to the artery by a band of fibrovascular tissue referred to as the ligament of Mayer. Each measures about 3-7 mm in greatest dimension and weighs 3-15 mg {894, 1034,2231,2879}. They function as chemoreceptors sensitive to changes in oxygen tension, carbon dioxide content and hydrogen ion concentration.

Jugulotympanic paraganglia

Small paraganglia with a structure similar to the carotid body have been described in the ear {957}. More than 50% of these structures are situated in relation to the jugular bulb; a minority are found under the mucosa of the middle ear in the region of the medial promontory wall. The tumours arising from these paraganglia form the more frequent jugular paraganglioma (glomus jugulare) and the less frequent tympanic paraganglioma (glomus tympanicum), respectively.

Vagal paraganglia

The vagus nerve (from the Latin "vagus" meaning wandering and meandering) arises from 8-10 rootlets on the lateral border of the medulla that converge to form a cord on entering the jugular foramen. It is the longest cranial nerve and has a superior ganglion, which lies within the jugular foramen, and just below this, a middle ganglion. A third, much larger ganglion, known as the ganglion nodosa, lies more inferiorly. It is approximately 2.5 cm long and lies high in the neck, just behind the internal carotid artery.

Vagal paraganglia do not form a discrete "body" as seen at the carotid artery bifurcation, but rather consist of 6-7 small, dispersed aggregates of paraganglionic tissue. They may be found within (intravagal), or adjacent to (juxtavagal), the vagus nerve, usually at the level of the nodose ganglion. In rare instances, paraganglionic tissue may be found in sites just above or below the nodose ganglion. Their function is unknown, but they may have a role as a chemoreceptor and moderator of the cardiopulmonary system.

Laryngeal paraganglia

The larynx contains two pairs of paraganglia that are divided into two groups: superior and inferior. The superior paraganglia are between 0.1 mm and 0.3 mm in diameter. They occur bilaterally in the upper one-third of the false cord, adjacent to the superior margin of the thyroid cartilage, in close proximity to the superior laryngeal artery and nerve {2731}.

The inferior paraganglia are also bilateral but larger than the superior group, averaging 0.3- 0.4mm in diameter {1331}.

Table 8.4 Differential diagnosis of paraganglioma of the head and neck.

Stain	Paraganglioma	Carcinoid	Medullary Thyroid Carcinoma	Anaplastic Carcinoma	Melanoma	Renal Cell Carcinoma
Synaptophysin	+	+	+	–	–	–
Keratin	–	+	+	+	–	+
HMB-45	–	–	–	–	+	–
Renal cell carcinoma antigen	–	–	–	–	–	+
Calcitonin	–	–/+	+	–	–	–
Thyroid transcription factor	–	–	+	–	–	–
Congo red (amyloid)	–	–	+	–	–	–

They characteristically occur between the inferior border of the thyroid cartilage and cricoid cartilage or between the cricoid cartilage and first tracheal ring in relationship to the inferior laryngeal artery and nerve.

Aberrant and accessory paraganglia are described {1331,2878}. Occasionally, paraganglia may even be found within nerves rather than adjacent to them. This is especially so regarding the recurrent laryngeal nerve {525}. The physiological role of the laryngeal paraganglia is also unknown. They may possibly serve as extracarotid chemoreceptors or have some effect on respiration via the larynx.

Terminology

The preferred terminology for tumours of the extradrenal paraganglia is "paraganglioma", prefaced by the anatomic site of origin, for instance, carotid body paraganglioma {1412}. If the tumour is functional or malignant, it would be designated, for example, as a functional carotid body paraganglioma or a malignant carotid body paraganglioma. Although the adrenal medulla is technically a paraganglion, a tumour arising from this site is still regarded as a phaeochromocytoma rather than a paraganglioma.

Diagnostic procedures

Computed tomography (CT) with contrast medium and magnetic resonance imaging (MRI) with gadolinium are invaluable in defining the location, size and extent of a paraganglioma {1587, 2124}. The typical CT appearance of a carotid body and vagal paraganglioma is that of a homogenous, hypervascular, well-defined soft tissue mass. If there has been haemorrhage or focal thrombosis, a heterogenous pattern of enhancement will be seen. CT scans of jugulotympanic paragangliomas may also show expansion and erosion of the jugular foramen. As the tumour expands, it may destroy the surrounding bony labyrinth and ossicular chain and extend into the region of the cerebellopontine angle {2124}.

MRI characteristics of all paragangliomas are similar. A well-defined hypointense mass with areas of signal void is typically seen on T1-weighed images {1587}. A "salt and pepper" pattern is commonly seen in all lesions larger than 2 cm. This pattern is usually seen on T2-weighed images and is due to areas of high vascularity associated with haemorrhage or slow blood perfusion. In addition to providing superior definition, MRI can also detect much smaller paragangliomas than CT scans.

Octreotide scintigraphy is an important adjunct. It can be used not only to confirm the diagnosis of a neuroendocrine neoplasm, but also to detect additional occult tumours, to separate postoperative changes from residual or recurrent disease and for screening patients at risk for familial paragangliomas {1398,1587}.

Ultrasound has a limited role in the evaluation of head and neck paragangliomas. It is useful in the evaluation and follow-up of carotid body paragangliomas and to some extent vagal paragangliomas. Its use in the detection and assessment of jugulotympanic paragangliomas is limited because of the surrounding bone.

Although non-invasive imaging has almost universally replaced angiography as the primary radiographic procedure for diagnosing paragangliomas, angiography still remains an important component in the management of these patients, especially in regards to preoperative embolization to reduce the blood supply of the tumour.

Genetics

It is commonly stated that about 10% of all paragangliomas of the head and neck are familial and inherited as an autosomal dominant trait with genomic imprinting {951,1670,2665}. There is no tumour when the gene is inherited from the mother. Paternal transmission of the gene, however, results in tumour(s) in children even if the father is clinically unaffected. Some investigators are of the opinion that because of skipping of generations after maternal transmission of the gene, that the incidence of familial paragangliomas is vastly underestimated and may be as high as 50% of all cases {2678}.

Genetic linkage analyses of several large families with hereditary paragangliomas have identified three loci associated with these tumours – paraganglioma 1 (PGL1) on chromosome 11q23, PGL2 on chromosome 11q13.1 and PGL3 on chromosome 1q21-q23 {1080,1634,1897}. Studies have identified the PGL1 gene as SDHD and the PGL3 gene as SDHC, both of which encode mitochondrial respiratory chain proteins {181,182,889}.

In a study of 8 patients with sporadic (non-familial) paragangliomas of the head and neck, 3 exhibited deletions at chromosome 11q, 2 at 11q22-23 and 1 at 11q13 {213}. This suggests that sporadic and familial paragangliomas may share a similar molecular-genetic pathogenesis.

It is now possible through genetic analysis to identify early on those patients who are at risk for familial paragangliomas, with the possibility of gene therapy on the horizon {2025}.

Carotid body paraganglioma

L. Barnes
L.L.Y. Tse
J.L. Hunt

Introduction
A neuroendocrine neoplasm derived from carotid body paraganglia composed of chief and sustentacular cells arranged in a characteristic (Zellballen) pattern.

ICD-O code 8692/1

Synonyms
Carotid body tumour, chemodectoma, glomus tumour, non-chromaffin paraganglioma, neuroendocrine tumour.

Age and sex distribution
They occur primarily in adults averaging 40-50 years of age and are rare in children. At sea level, the sex distribution ranges from 1:1-1:4 in favour of females {136,951,1410,1869,2155}. However, at altitudes above 2000 meters, there is a female predominance of 8.3:1 {2188}. It has been postulated that the monthly loss of blood through menstruation in women and a larger pulmonary capacity and greater enthusiasm for sports and athletic conditioning in men may allow males to escape chronic hypoxia and account for this wide gender gap {2188}.

Etiology
Familial inheritance and chronic hypoxia are the only known risk factors.

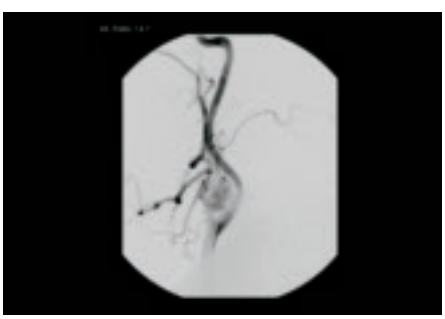

Fig. 8.1 Carotid body paraganglioma. Angiogram shows a hypervascular mass at the bifurcation of the common carotid artery with separation of the internal and external carotid arteries. Courtesy of Drs. Jim Rabinov and Hugh Curtin, Department of Radiology, Massachusetts General Hospital, Boston, MA, USA.

Localization
The tumours occur at the bifurcation of the common carotid artery with no significant lateralization to either side of the neck. As they enlarge, they may become adherent, invade or incorporate the external and/or internal carotid arteries.

Clinical features
Although uncommon, carotid body paragangliomas are regarded as the most common paraganglioma of the head and neck.

Signs and symptoms
The typical presentation is that of a slowly enlarging, asymptomatic mass deep to the anterior border of the sternocleidomastoid muscle just below the angle of the mandible. The tumour can be moved from side to side but with little or no movement in a vertical plane (Fontaine's sign). Occasionally, it may be associated with pain, hoarseness, dysphagia, Horner's syndrome, headache, syncope, bruit or thrill. Functional tumours with catecholamine – induced hypertension are exceptional {509}.
Infrequently, the tumour may be bilateral or associated with paragangliomas in other sites (usually a vagal or jugulotympanic paraganglioma) or occur in combination with a phaeochromocytoma, a well-differentiated thyroid carcinoma or a component of multiple endocrine neoplasia syndrome or Carney triad {481,509, 1391,1422,1430}. Hereditary deficiencies of clotting factors VII and X have also been observed in a few patients with familial carotid body paragangliomas {1376}.

Imaging
Carotid body paragangliomas appear on angiography as hypervascular masses at the carotid artery bifurcation with eventual splaying of the internal and external carotid arteries.

Macroscopy
The tumours are usually between 2.0 and 6.0 cm (average 3.8 cm) and are firm, rubbery, well circumscribed, and invested by a thin, sometimes focally thickened fibrous capsule. On cut surface, most have a variegated yellow, tan, pink, red or brown appearance with areas of fibrosis and haemorrhage. A few are homogenously tan-pink or yellow-brown. A large artery, usually the external carotid, is occasionally seen occurring through the tumour or attached peripherally.

Fig. 8.2 Carotid body paraganglioma. Cut surface showing encasement of a segment of external carotid artery which had to be sacrificed.

Histopathology
These highly vascular tumours are composed of two cell types, chief and sustentacular, arranged in a characteristic alveolar or Zellballen pattern. The chief cells (type I cells, epithelioid cells) are more numerous and contain catecholamine-bound neurosecretory granules as seen ultrastructurally. The sustentacular cells (type II cells, supporting cells) are devoid of neurosecretory granules and are characteristically located at the periphery of the Zellballen.
The chief cells often show considerable nuclear enlargement and hyperchromatism and contain cytoplasm that varies from pink to clear, to amphophilic and which may be vacuolated. Spindle-shaped chief cells are uncommon and mitoses are sparse to absent. Vascular and perineural invasion are infrequent and have no prognostic significance.

Immunoprofile
The chief cells express synaptophysin,

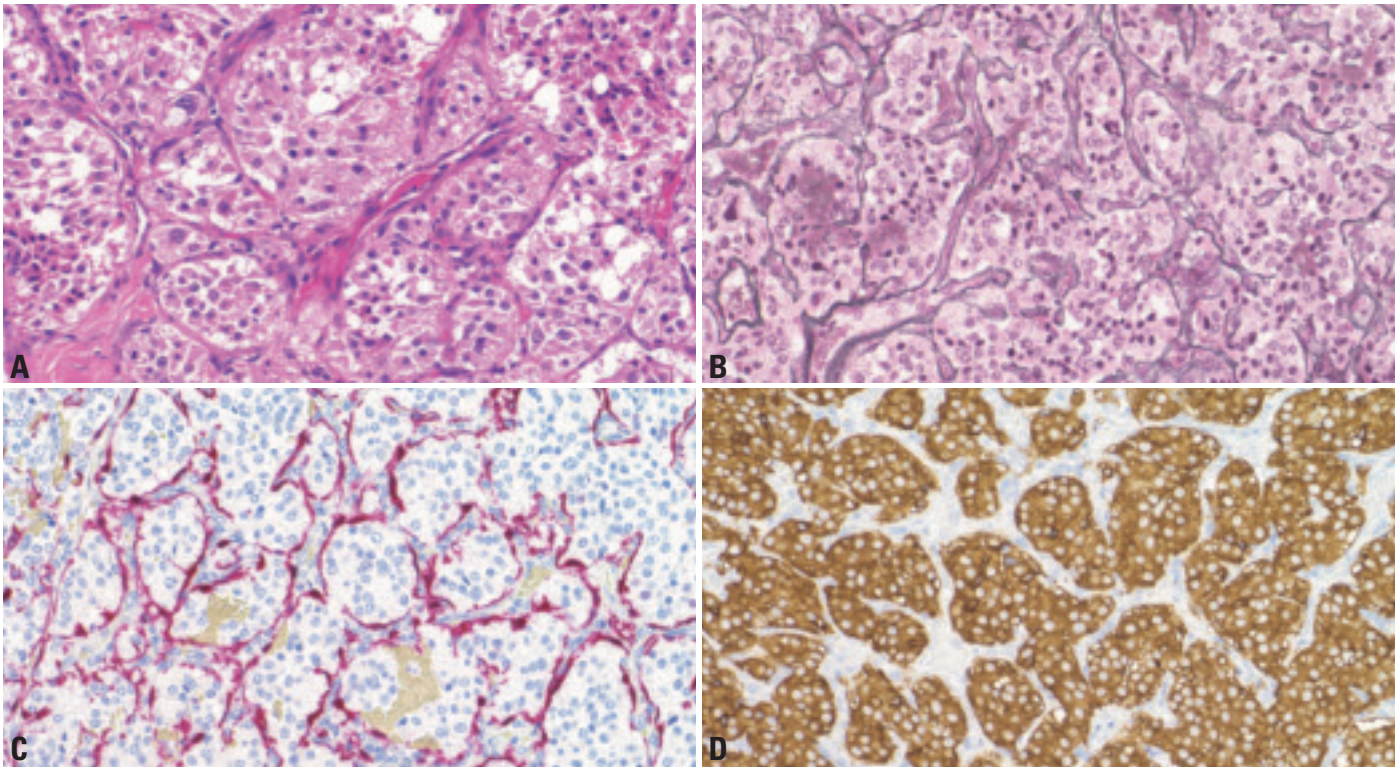

Fig. 8.3 Carotid body paraganglioma. **A** Note the alveolar (Zellballen) arrangement of the chief cells, anisonucleosis and the prominent capillary network around each group of cells. **B** Reticulin stain accentuates the alveolar (Zellballen) arrangement of chief cells. **C** S-100 protein highlights the peripheral layer of sustentacular cells surrounding each group of cells. **D** The chief cells are strongly positive for synaptophysin; sustentacular cells are negative.

chromogranin and neuron-specific enolase. They are negative for cytokeratin, carcinoembryonic antigen, S-100 protein and calcitonin. The sustentacular cells express S-100 protein and glial fibrillary acidic protein.

Malignant carotid body paraganglioma

Paragangliomas are divided into non-invasive (circumscribed, encapsulated), locally invasive and metastatic categories. Some locally invasive tumours may even cause the death of the patient. Although clinically malignant, these tumours are still regarded as locally invasive. A tumour is considered malignant only if there is metastasis to regional lymph nodes or to more distant sites, such as the lungs and bones.

The incidence of malignant (metastasizing) carotid body paragangliomas ranges from 2-13% {136}. Unfortunately, the clinical behaviour cannot be predicted on the basis of routine histology. Such features as nuclear pleomorphism, mitotic activity, necrosis and vascular – perineural invasion are unreliable prognosticators and have been found in benign as well as malignant tumours {136}. Other findings such as DNA ploidy, absence of sustentacular cells, number of expressed neuropeptides, assessment of argyrophilic nucleolar organizer regions and proliferative markers (PNCA, Ki-67) show no consistent correlation with histological behaviour {661,871,1335,1336, 1382, 1526,2678,2748,136,}.

Sporadic (non-familial) carotid body paragangliomas are more likely to be malignant than those that are familial – 12% versus 2.5% {951}. Metastases may be apparent at the time of initial therapy or may not become apparent until 20 years later {1967}.

Surgery with or without adjuvant irradiation is used for local disease. Chemotherapy, however, is largely ineffective {1656}. The overall 5-year relative survival is 59.5%. If the metastases are confined to regional lymph nodes, the 5-year survival is 76.8% but decreases to 11.8% for patients with distant metastases {1451}.

Differential diagnosis

The differential diagnosis includes carcinoid, medullary thyroid carcinoma, anaplastic carcinoma, metastatic melanoma and renal cell carcinoma. Immunostains are useful in separating these tumours.

Genetics

One-third of familial carotid body paragangliomas are bilateral, as opposed to 4% bilateral sporadic (non-familial) cases {951}. These may appear synchronously or asynchronously.

C-myc, bcl-2 and c-jun are abnormally expressed in some tumours and may contribute to tumourigenesis {2719, 2721}. Overexpression of TP53, however, does not appear to be an etiologic factor {2720}.

Prognosis and predictive factors

Carotid body paragangliomas are slowly growing tumours with a median growth of 0.83 mm per year and a median doubling time of 7.13 years {1205}.

Surgery, often with sacrifice of one or more branches of the carotid arterial system, is the treatment of choice. Somewhere between 0-10% of tumours will recur. This is not necessarily a sign of malignancy but rather inadequate excision and regrowth.

Jugulotympanic paraganglioma

L. Michaels
S. Soucek
T. Beale
A. Sandison

Definition
A neoplasm arising from one or other of the paraganglia situated in the vicinity of the jugular bulb or on the medial promontory wall of the middle ear.

ICD-O code 8690/1

Synonyms
Jugulotympanic chemodectoma, glomus jugulare tumour, jugular glomus tumour, glomus tympanicum tumour, tympanic glomus tumour.

Epidemiology
Solitary jugulotympanic paragangliomas arise predominantly in females. The age range is between 13 and 85 years with a mean age of about 50 years. The familial type occurs predominantly in men.

Localization
Most jugulotympanic paragangliomas arise from the paraganglion situated in the wall of the jugular bulb. A minority arise from the paraganglion situated near the middle ear surface of the promontory. The distinction between jugular and tympanic paragangliomas can easily be made in the patient by modern imaging methods with which the jugular neoplasm is identified as arising from the jugular bulb region and shows evidence of invasion of the petrous bone, while the tympanic neoplasm is confined to the middle ear. Jugulotympanic paragangliomas may also be multicentric or coexist with tumours of other types. They may be bilateral in the same patient and coexist with carotid body paragangliomas which may also be bilateral {1949}. They may also coexist with adrenal gland pheochromocytomas.

Clinical features
Most patients present with conductive hearing loss. Pain in the ear, facial palsy, haemorrhage, and tinnitus are also described. On examination, a red vascular mass is seen either behind the intact tympanic membrane or sprouting through the latter into the external canal. Surgical approach to the mass at biopsy often results in severe bleeding.

Etiology
The etiology of the solitary type is unknown. In the multiple familial type there is evidence of a gene mutation on chromosome 11.

Macroscopy
The neoplasm is an irregular reddish mass. In the jugular variety, the petrous temporal bone and the middle ear space are largely replaced by red, firm material as far as the tympanic membrane. The otic capsule is rarely invaded by paraganglioma.
Investigation of a paraganglioma in an autopsy temporal bone by the microslicing method, showed the shape of the jugular bulb to be retained, but the lumen was completely filled by neoplasm. The tumour invaded the apical region of the petrous temporal bone and the middle ear space was completely filled by neoplasm as far as the tympanic membrane. However, the surgical specimen is usually fragmented.

Histopathology
The histological appearances of the jugular and tympanic paragangliomas are similar, resembling that of the carotid body paraganglioma. Epithelioid, small, uniform cells, with finely granular cytoplasm are separated by numerous blood vessels. The tumour cells often form clusters or "Zellballen" with peripheral flattened cells. Nuclei are usually uniform and small, but diagnosis is sometimes made difficult by the presence of bizarre or multinucleate cells which, however, do not indicate malignancy. A prominent fibrous stroma is sometimes present.

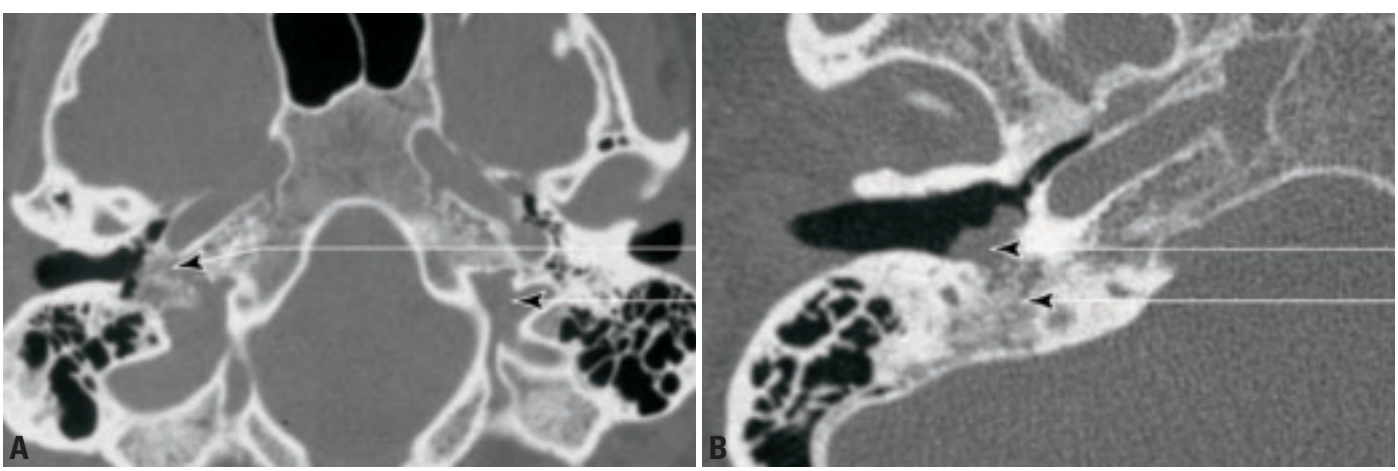

Fig. 8.4 Jugulotympanic paragangliomas. **A** Axial CT scan of petrous bone. On the right side, there is erosion of the cortex of the jugular foramen in keeping with a jugular paraganglioma (upper arrow). Note the normal jugular foramen (lower arrow) on the left. **B** Axial CT scan of petrous bone. Soft tissue mass in the posterior hypotympanum (upper arrow). The adjacent permeative erosion (lower arrow) suggests that this is a tympanic paraganglioma.

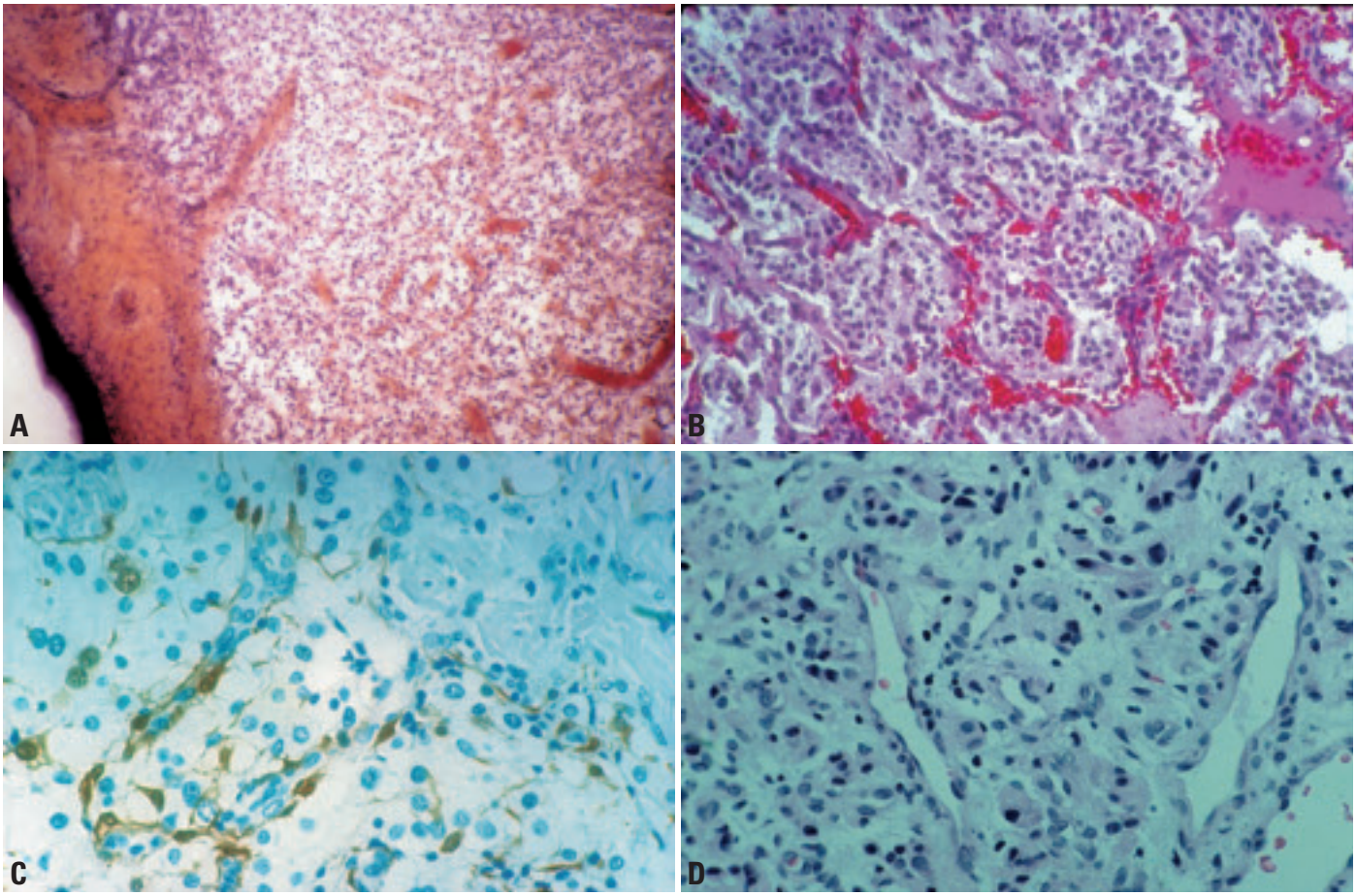

Fig. 8.5 Jugulotympanic paragangliomas. **A** Section of autopsy case of jugulotympanic paraganglioma showing tumour behind tympanic membrane. **B** Histological appearance of jugulotympanic paraganglioma. **C** Jugulotympanic paraganglioma showing numerous sustentacular cells (S100 protein). **D** Jugulotympanic paraganglioma showing bizarre cells some of which are multinucleate.

Immunoprofile

The immunoprofile of these tumours has been covered in an earlier section (Immunoprofile p. 364-365).

Electron microscopy

Paragangliomas shows membrane-bound, electron-dense neurosecretory granules in the cytoplasm of the tumour cells consistent with catecholamine content {2277}.

Prognosis and predictive factors

Jugulotympanic paraganglioma is a neoplasm of slow growth. The jugular variety infiltrates the petrous bone, but distant metastasis is rare. Radiation therapy, and in some cases surgery, offers a high rate of cure for the localized neoplasms.

Vagal paraganglioma

L. Barnes
L.L.Y. Tse
J.L. Hunt

Definition
A neuroendocrine neoplasm derived from paraganglia found within or adjacent to the vagus nerve usually in the vicinity of the ganglion nodosum.

ICD-O code 8693/1

Synonyms
Vagal body paraganglioma, glomus tumour, glomus vagale, chemodectoma, non-chromaffin paraganglioma, neuroendocrine tumour.

Epidemiology
Age and Sex distribution
Vagal body paragangliomas are more common in women (64%) and occur over a broad age range (19-86 years) with an average of 45-55 years {215,282,689, 1410,1411,1736,1868,2659}.

Etiology
Most are sporadic. Some are related to familial inheritance. Although chronic hypoxia may lead to hyperplasia of vagal paraganglia, there is no conclusive evidence, in contrast to the carotid body paraganglioma, that it leads to the development of a vagal paraganglioma {1409}.

Localization
The tumours typically occur in the rostral portion of the vagus nerve in the vicinity of the ganglion nodosum. In a review of 99 vagal paragangliomas in which the side of origin was indicated, 56% arose on the right side of the neck, 39% on the left side and 5% were bilateral {2879}.

Clinical features
The vagal paraganglioma is the third most frequent paraganglioma of the head and neck, exceeded in frequency only by the carotid body and jugulotympanic paragangliomas. It characteristically presents as a slowly enlarging, asymptomatic mass at the angle of the mandible and/or as a bulge in the lateral oropharyngeal wall. As it increases in size, deficits of cranial nerves IX, X, XI and XII and the cervical sympathetic chain are common, resulting in unilateral vocal cord dysfunction, dysphagia, atrophy of the tongue, shoulder weakness and Horner syndrome. At the time of diagnosis, anywhere from 35-65% of patients may manifest one or more cranial nerve deficits.
Functional tumours with catecholamine-induced hypertension are distinctly uncommon, occurring in only 3.6% of all tumours.

Table 8.5 Vagal paraganglioma: clinico-pathologic features*

Average age (n=139)	45 – 55 years (range 19 – 86 years)
Gender (n=139)	64% female (range 50 – 85%)
Multicentric tumours (n=124)	33% (range 10 – 46%)
Familial history (n=124)	17% (range 0 – 47%)
Functional tumours (n=139)	3.6% (range 0 – 11%)
Local recurrence (n=126)	8% (range 0 – 20%)
Malignant tumours (n=139)	7% (range 0 – 16%)

*Data based on references {215,282,689,1410,1411,1736,1868,2659}.

Imaging
Vagal paragangliomas are highly vascular and are located in the suprahyoid neck, well above the level of the carotid bifurcation and typically displace both external and internal carotid arteries anteromedially.

Macroscopy
The tumours are fusiform or circular and abut directly onto the base of the skull. They usually range from 2.0-6.0 cm and are firm, rubbery, well circumscribed and surrounded by a thin, sometimes focally thickened fibrous capsule. In a few instances, they may be poorly defined and locally infiltrative.
On cut surface, they have a variegated yellow, tan, pink, red or brown appearance with fibrosis and haemorrhage or they may be uniformly homogenous. A portion of one or more large nerves, usually the vagus, is often attached.

Histopathology
The histopathology, immunoprofile, ultrastructural features and differential diagnosis are similar to those previously

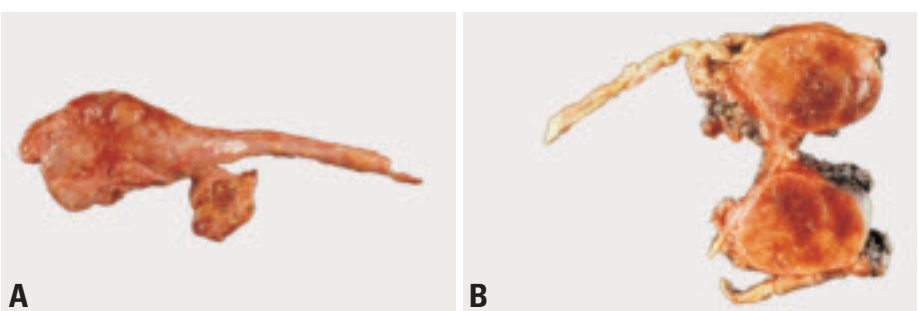

Fig. 8.6 Vagal paraganglioma. **A** Note the expanded portion of the vagus nerve which represents the neoplasm. A small group of lymph nodes is attached at the center of the specimen. **B** Cross section shows a spongy, focal haemorrhagic tan surface. A segment of vagus nerve is attached.

described for the carotid body paraganglioma.

Malignant vagal paraganglioma

Overall 7% of vagal paragangliomas are malignant by virtue of metastases. In one review of 15 malignant vagal paragangliomas, 73% were associated with cervical lymph node metastasis and 27% with distant metastases (lung, bone, liver and brain) {1050}. Most metastases are apparent either at or within four years of diagnosis.

Genetics

Patients with sporadic (non-familial) vagal paragangliomas may have more than one paraganglioma and should always be evaluated for this possibility. The incidence of finding multiple tumours in this population varies according to the thoroughness of the examination and the length of follow-up. When multiple, the tumours may appear synchronously or asynchronously. In a collective review of 124 vagal paragangliomas, 33% were associated, either at the time of diagnosis or on follow-up, with additional paragangliomas, usually a carotid body or, less frequently, a jugulotympanic paraganglioma. Seventeen percent of patients also had a family history of paragangliomas.

DNA analysis of 10 vagal paragangliomas utilizing image analysis, revealed 5 to be diploid, 4 diploid – tetraploid and 1 aneuploid {137}. DNA abnormalities are, therefore, common in these tumours and cannot be used to predict prognosis.

Prognosis and predictive factors

Vagal paragangliomas are slowly growing with an estimated median growth rate of one millimetre per year and a median doubling time of 8.89 years {1205}.

Options for treatment include surgical resection, radiation, and, in selected cases due to their slow growth rate, even observation. Most clinicians favour surgery. Almost invariably, the vagus nerve and sometimes even other cranial nerves, have to be sacrificed. In those instances where the nerve is preserved, function typically remains permanently impaired. Failure to remove the nerve may also predispose the patient for future recurrence.

Radiation is used for elderly patients who are poor operative risks or for those unfortunate individuals who have bilateral vagal paragangliomas (the larger tumour is preferentially excised while the smaller one is irradiated).

Following surgery, 8% of vagal paragangliomas will develop local recurrence. The tumour may recur as early as 12 months after therapy or as late as 22 years. Local recurrence is not necessarily a sign of malignancy but often results from inadequate excision.

Laryngeal paraganglioma

L. Barnes
L.L.Y. Tse
J. Hunt

Definition
A neuroendocrine neoplasm derived from either the superior or inferior paraganglia of the larynx composed of chief and sustentacular cells arranged in a characteristic organoid (Zellballen) pattern.

ICD-O code 8693/1

Synonyms
Glomus tumour, chemodectoma, non-chromaffin paraganglioma, neuroendocrine tumour.

Age and sex distribution
Laryngeal paragangliomas are rare, with only 62 cases identified in a critical review of the world literature in 1994 {125,739}. They are three times more common in women and have been described in patients from 5-83 years of age (median 44 years) {739,2586}.

Etiology
Other than a familial inheritance, there are no known risk factors.

Localization
The vast majority (82%) occur in the supraglottic larynx, presumably arising from the superior pair of laryngeal paraganglia, and present as a submucosal mass in the region of the aryepiglottic fold – false vocal cord {125}. Only 15% occur in the subglottis and 3% in the glottis. The right side of the larynx is more often involved than the left by a ratio of 2.3:1 {125}.

Clinical features
Most patients present with more than one complaint and have been symptomatic for an average of 26 months (median 23 months; range 3 weeks to 12 years) {125}. The major symptom, by far, is hoarseness. Others, in decreasing order of frequency, are dysphagia, dyspnea, stridor, dysphonia, sore-painful throat, neck mass, haemoptysis, coughing, shortness of breath, foreign body sensation in the throat, and otalgia. Bruits and pulsation are usually absent.

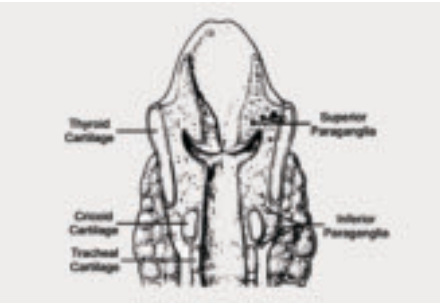

Fig. 8.7 Diagram of the larynx showing location of laryngeal paraganglia.

Functional laryngeal paragangliomas are exceptional with only one possible case report {1438}. The patient, a 25-year-old woman with a supraglottic paraganglioma had sinus tachycardia and hypertension, which disappeared following surgical removal of the tumour. Neither the patient nor the tumour was evaluated for hormone production. Other alleged functional tumours that have been reported are probably atypical carcinoids {1184,1240,2691}.

Imaging
Very few laryngeal paragangliomas have been evaluated preoperatively with angiograms. Of those that have, the blood supply of supraglottic paragangliomas has been from the superior thyroid artery, superior laryngeal artery or a branch of the external carotid artery {125,149,1123,1357,2236}. An angiogram of a single case of a subglottic paraganglioma showed the blood supply was via the thyrocervical trunk {1940}.

Macroscopy
The tumours characteristically present as a well-circumscribed, tan, brown or reddish-brown 0.5-6.0 cm (average 2.6 cm) submucosal mass {125}. Cut surface varies from smooth to multinodular, with or without areas of fibrosis.

Histopathology
Histopathology, immunoprofile, ultrastructural features and differential diagnosis are similar to those of the carotid body paraganglioma.

Malignant laryngeal paraganglioma
Although commonly stated that 25% of all laryngeal paragangliomas are malignant {851,2413,2779}, a critical review of these cases has revealed that almost all of these are examples of atypical carcinoids incorrectly labelled as malignant paragangliomas {125}.
Current studies indicate that only about 2% of all laryngeal paragangliomas are malignant {739}. Only a single acceptable case has been reported. This involved a 36 year-old woman with a paraganglioma of the larynx that metastasized to the lumbar spine 16 years after the diagnosis {96,2212}.

Genetics
Laryngeal paragangliomas may be associated with paragangliomas in other sites {125}. The most frequent association is with a carotid body paraganglioma {1020,2236,2679}. Cases have also been described associated with a jugulotympanic and a tracheal paraganglioma {510,1328}. Another example has been reported in a 35 year-old man with a family history of carotid body paragangliomas who presented with a subglottic paraganglioma {254}.
DNA analysis of two laryngeal paragangliomas has shown both to be diploid {125}.

Prognosis and predictive factors
Surgery is the treatment of choice, preferably through an external approach {739}. Endoscopic excision should be avoided (even for small lesions) because bleeding, which may be diffuse, may be difficult to control. Preoperative angiography and embolization, in an attempt to devascularize the tumour, is not essential since the superior thyroid artery can easily be ligated prior to resection. An elective neck dissection is not warranted. Seventeen per cent of patients have developed local recurrence from 1-16 years after initial excision {125}.